Laparoscopy – Laparotomy

Dr. Pravin Mhatre
Prof. Emeritus

Laparoscopy Vs Laparotomy

- Better visualization by
  - magnification
  - 30^0 optic
- shorter hospital stay
- less damage to healthy tissue
- better end result
- less pop pain
- less adhesions
- Risk for complications and their delayed diagnosis (blind entry)

- Less operation time
- Longer hospital stay
- More pop pain
- More damage to healthy tissue
- Overall more complications than laparoscopy !

"Doing least, and that too only if and when MUST"

Larger wound – more damage to fascia, muscle and nerves

- loss of water and heat, drying out of tissues,
- more handling causes trauma
- Leading to adhesions and impaired healing.

Open surgery through small incisions – more retraction leading to parietal hematoma, neuropraxia.

- Magnification and good illumination gives much better view than open surgery, specially in pelvic surgery.

- Endoscopic surgery is safer for the surgeon as there is reduced chance of contact between patient's body fluids and viscera

- The biggest input is from other surgeons and not soley by operating one

"It's keyhole surgery. I'll be operating on you from behind that locked door."

Anatomic evaluation
Teaching
Diagnosis
Treatment
Adhesions
Second look

Ureter

- All abdominal surgeons are encouraged to study and become familiar with retroperitoneal anatomy and dissection techniques.
- With advanced video laparoscopic technology, pelvic structures can be **magnified** onto the TV monitor in minute detail.
- The positive intra-abdominal pressure of the pneumoperitoneum exerted against covering peritoneum highlights the underlying ureter in **remarkable detail.**

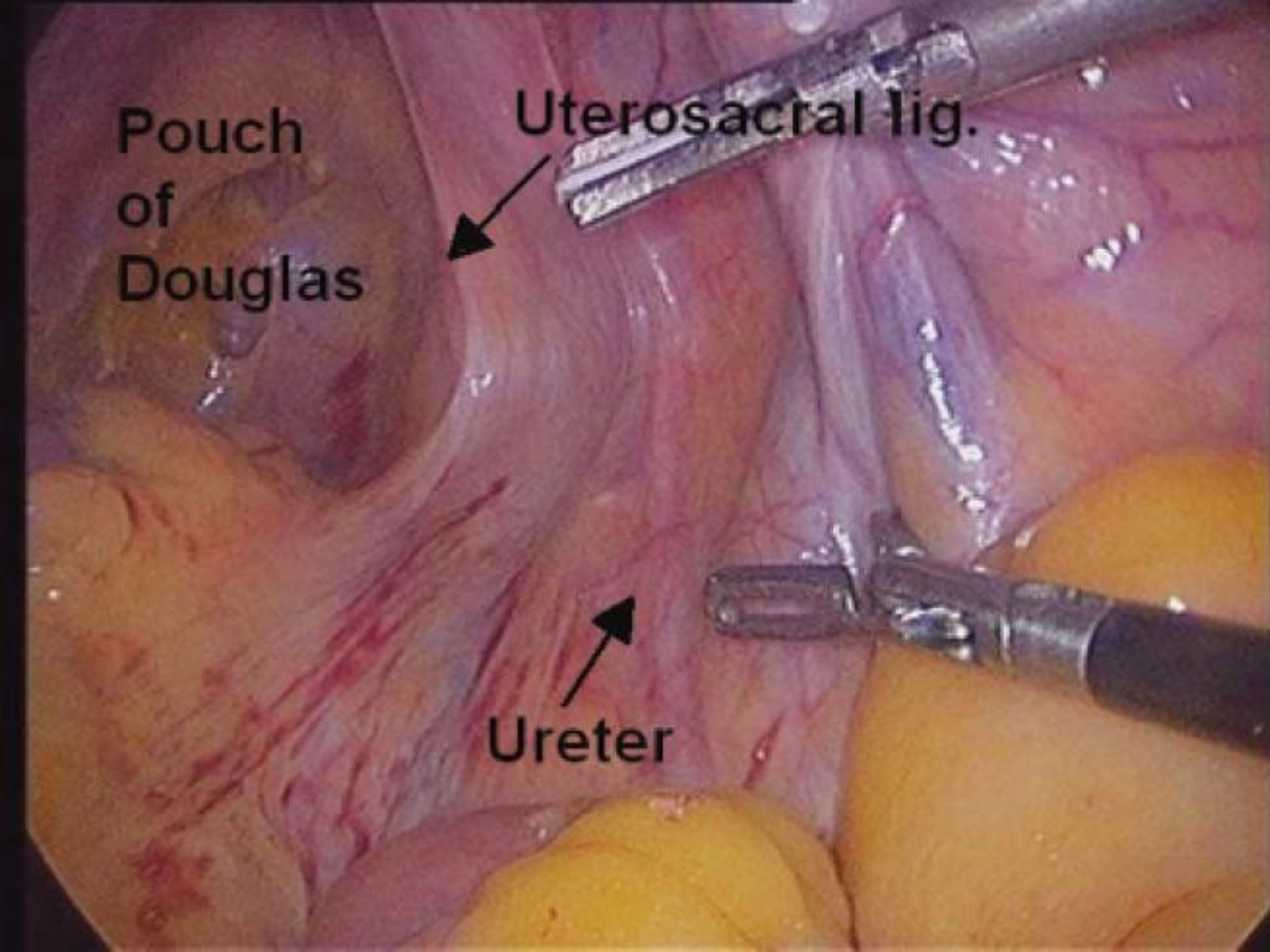
Pouch
of
Douglas
Uterosacral lig.
Ureter

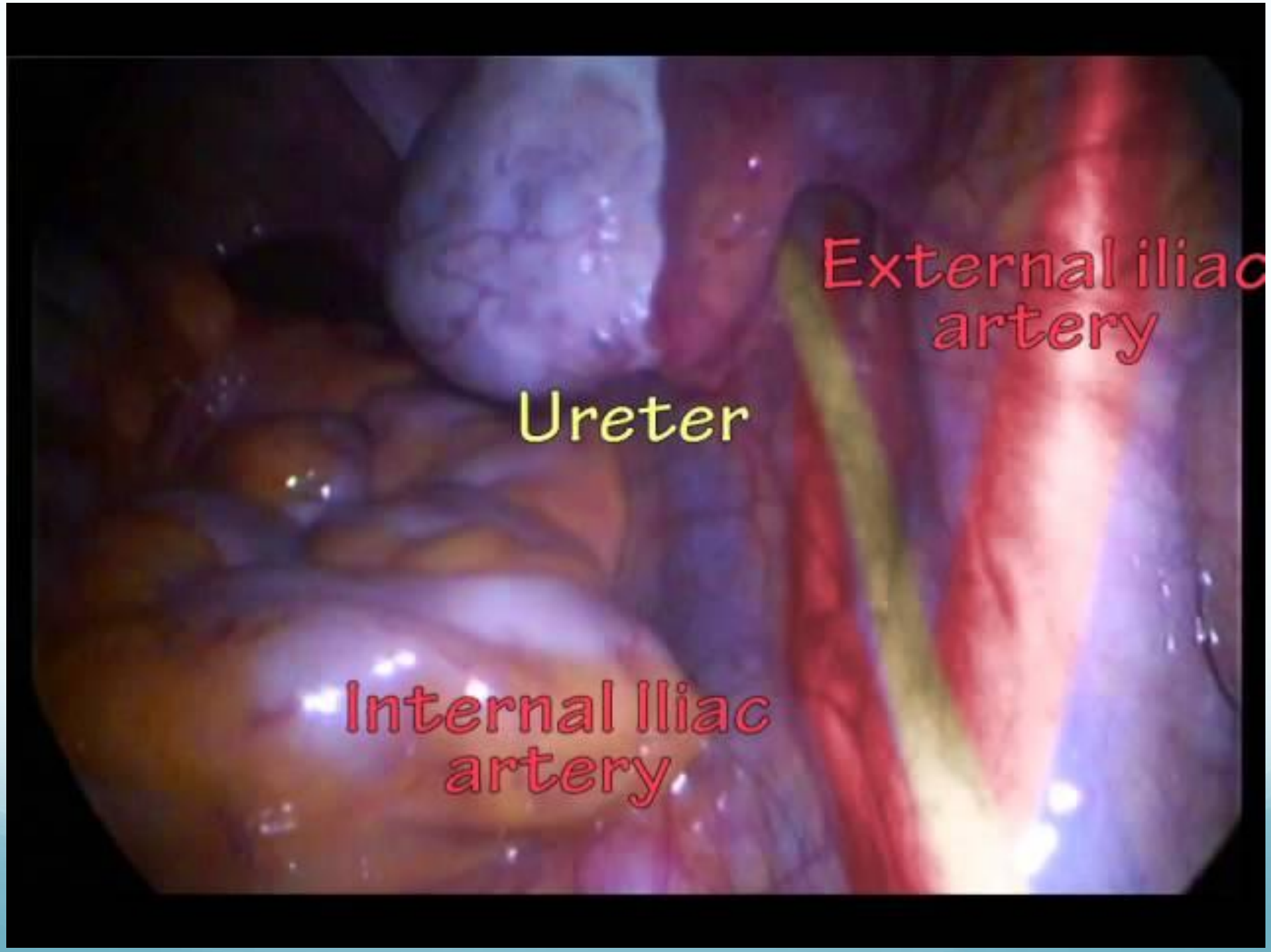
External iliac
artery
Ureter
Internal Iliac
artery

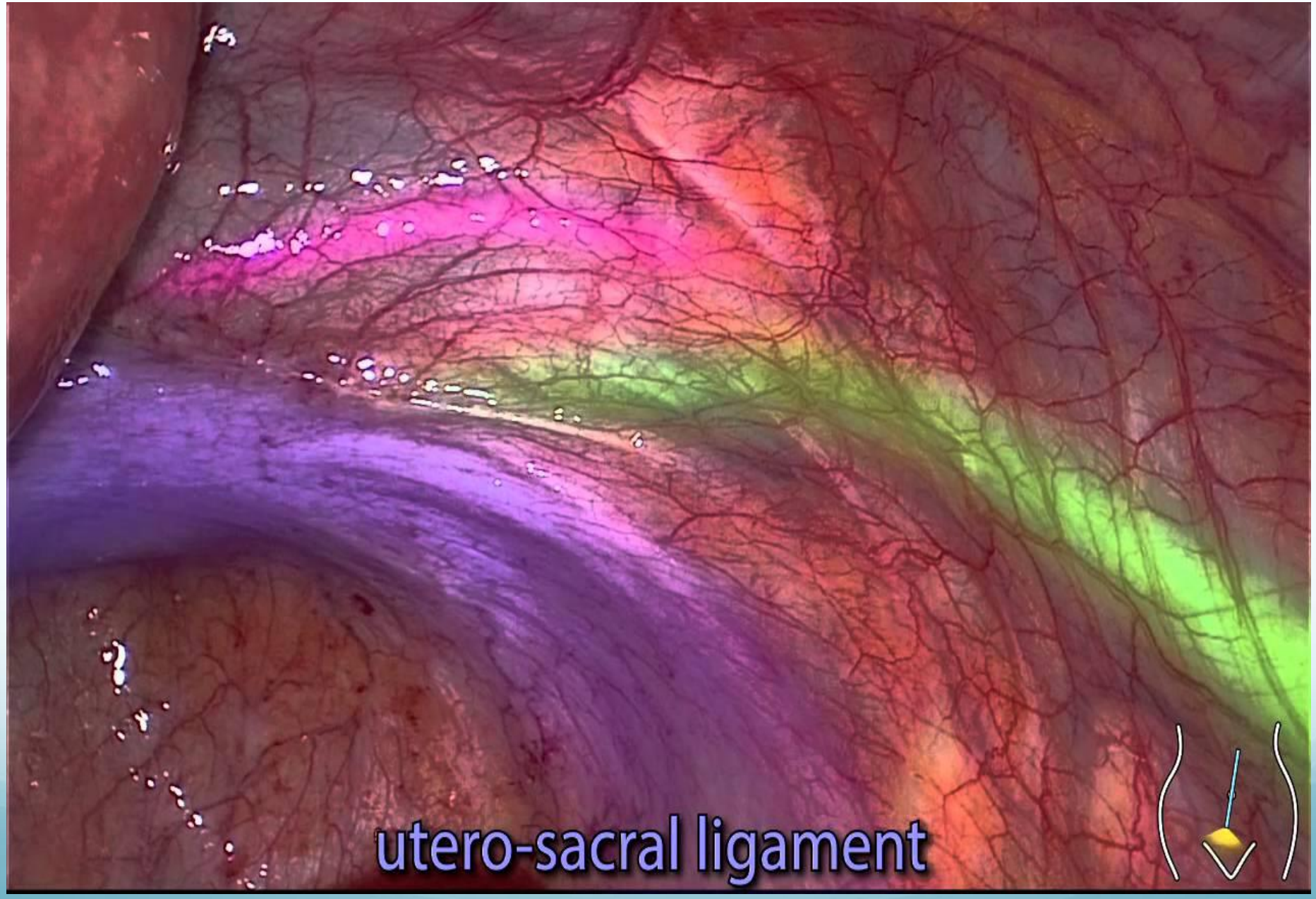
utero-sacral ligament

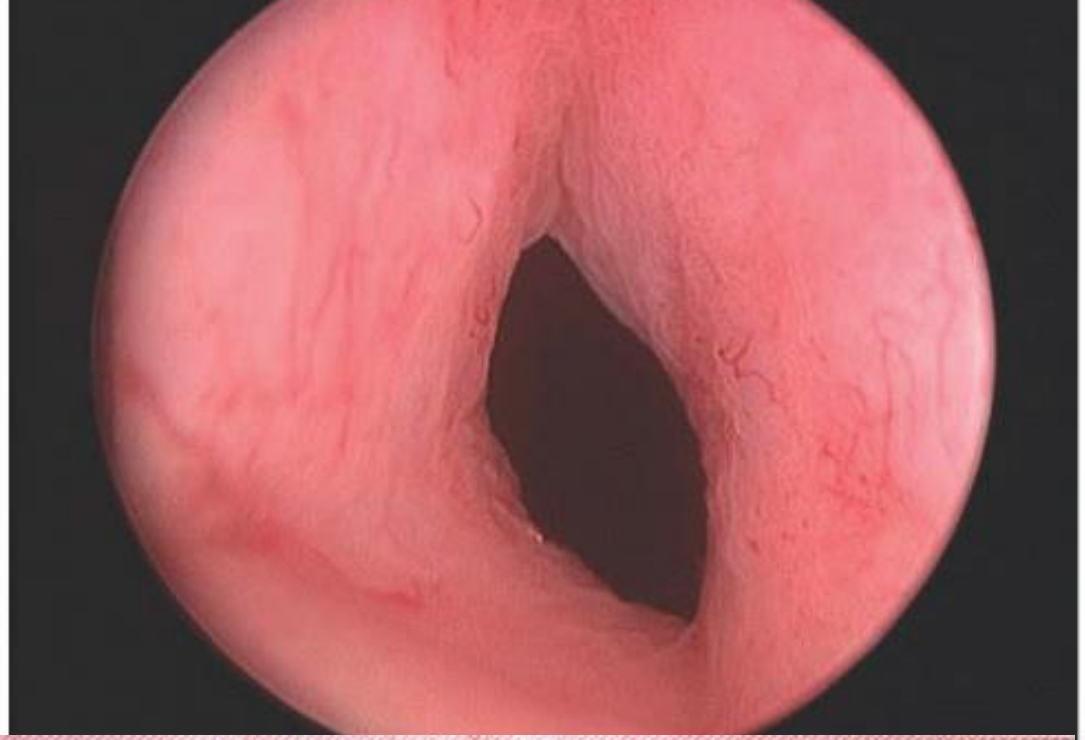

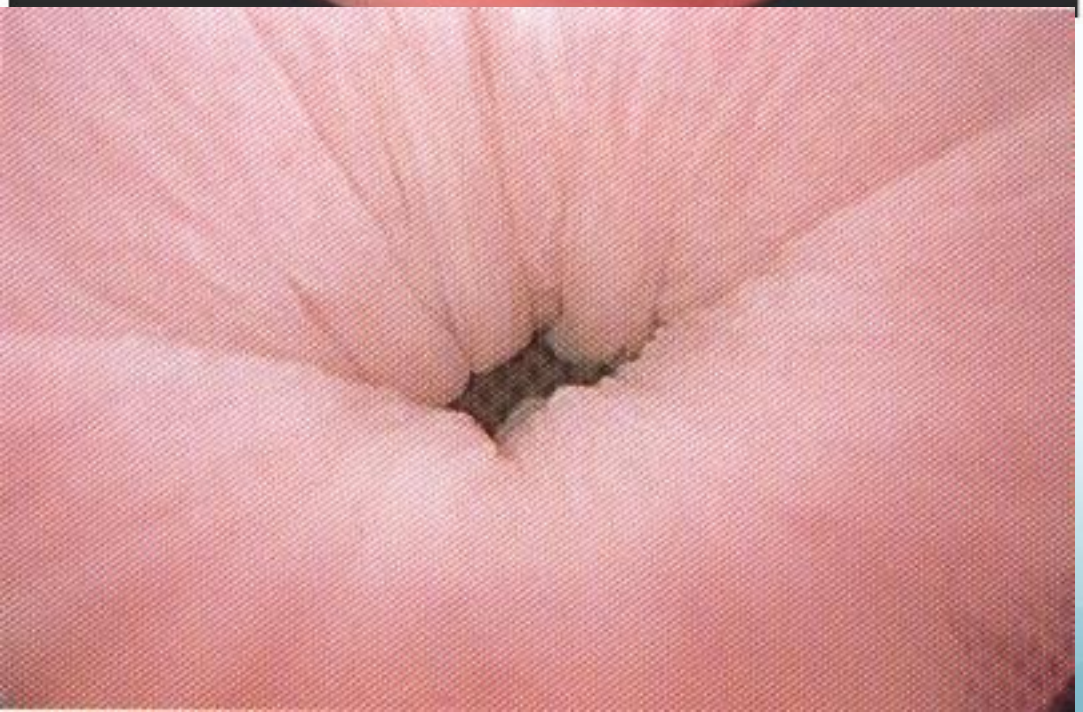

Urethal closure and midurethral elevation

Learning physiology /anatomy
SUI-Diagnosis and Treatment

Ureteric implantation-physio/antomic

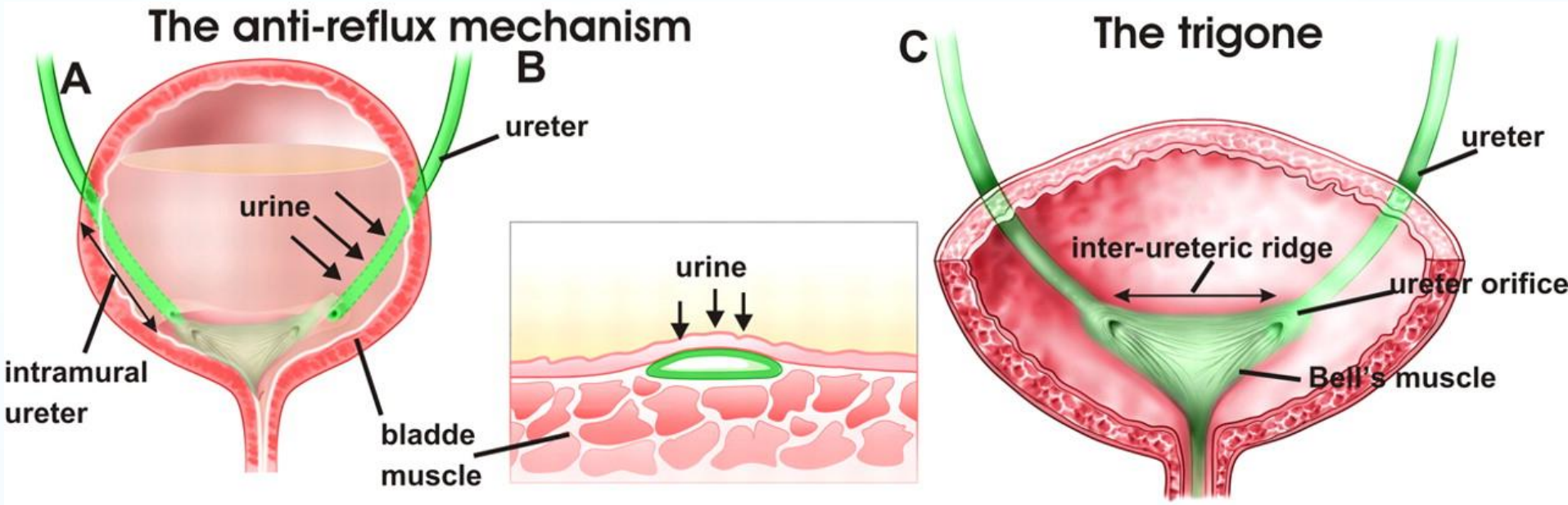

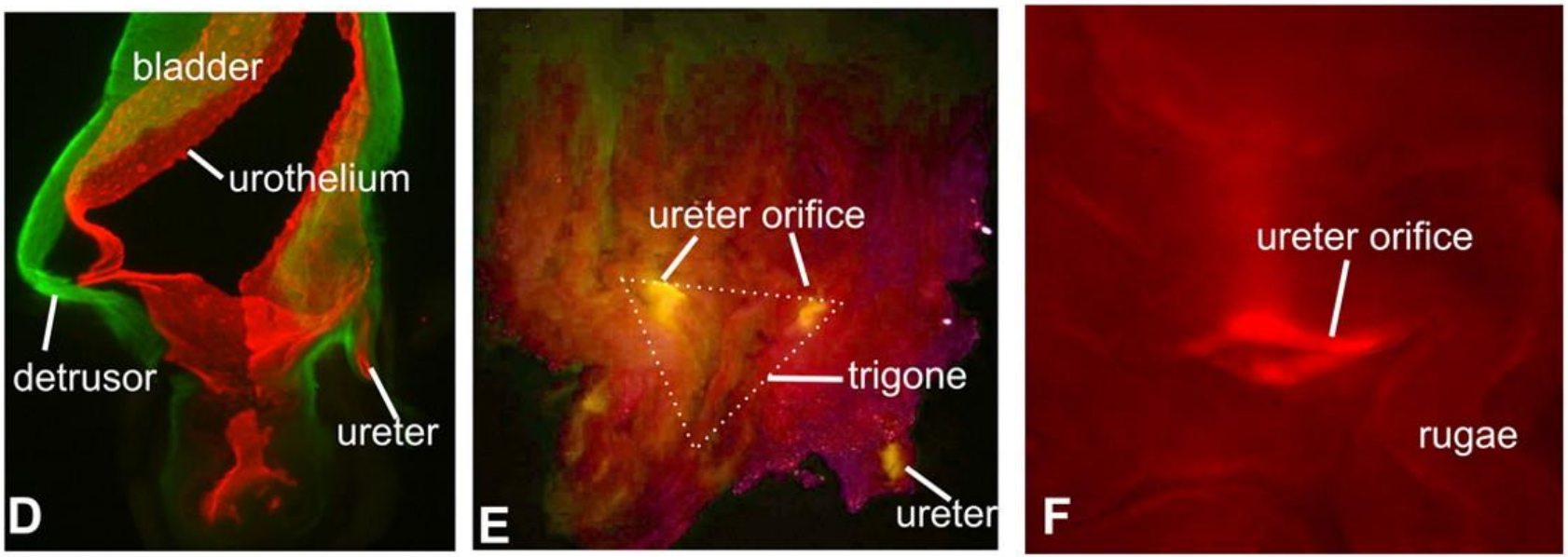

Ureteral repair

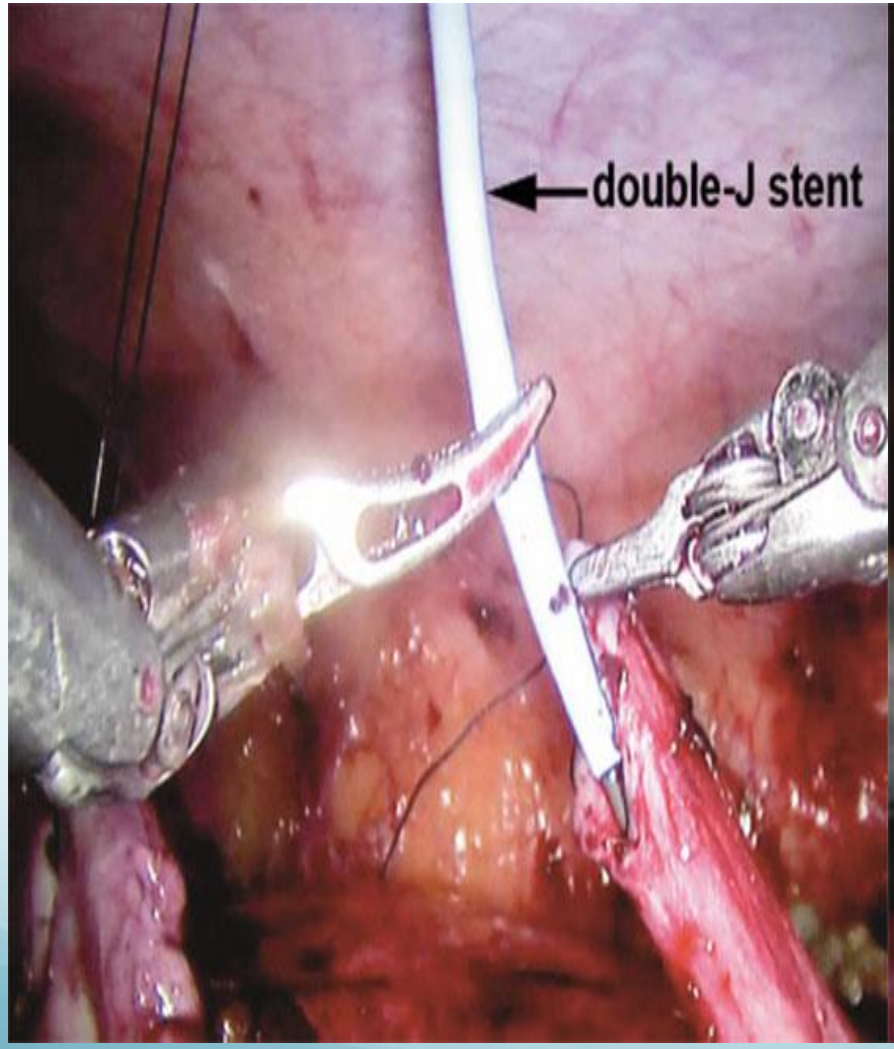

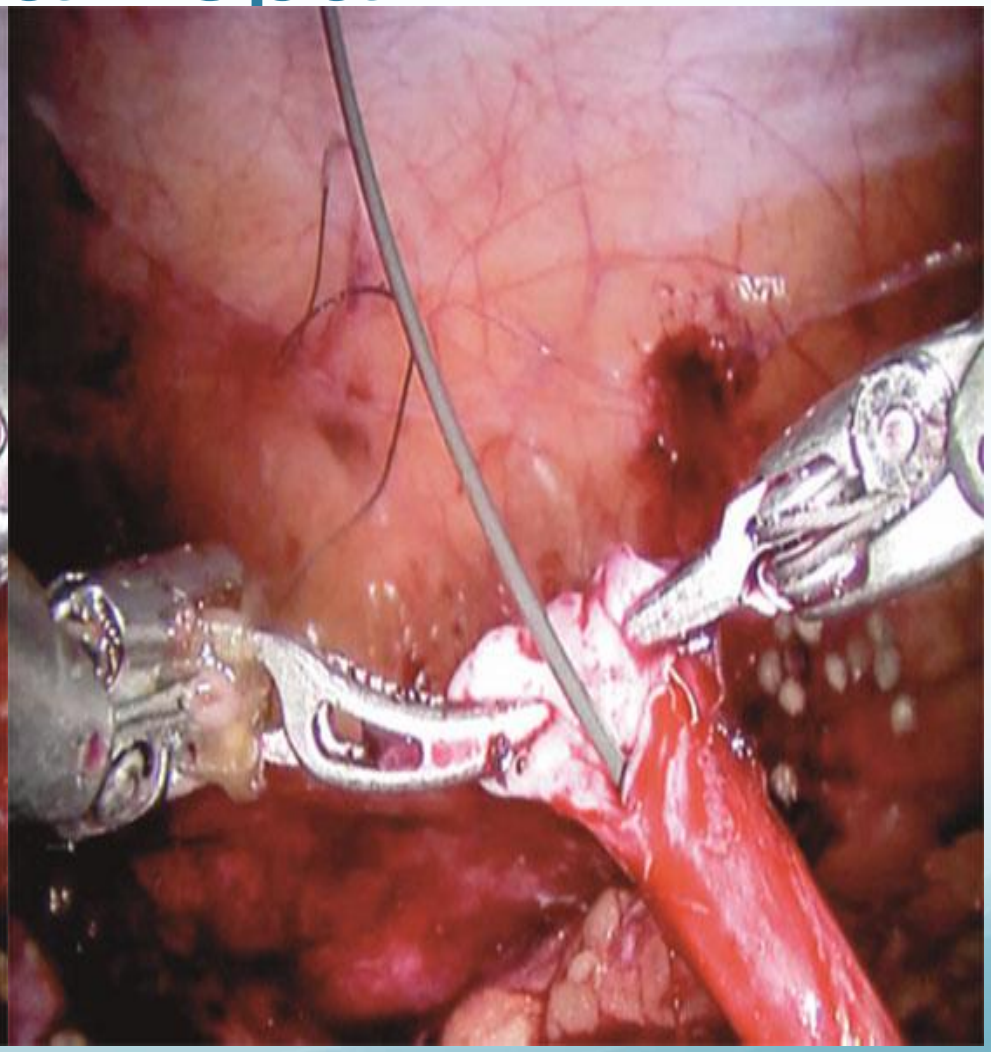

Ureter at laparotomy

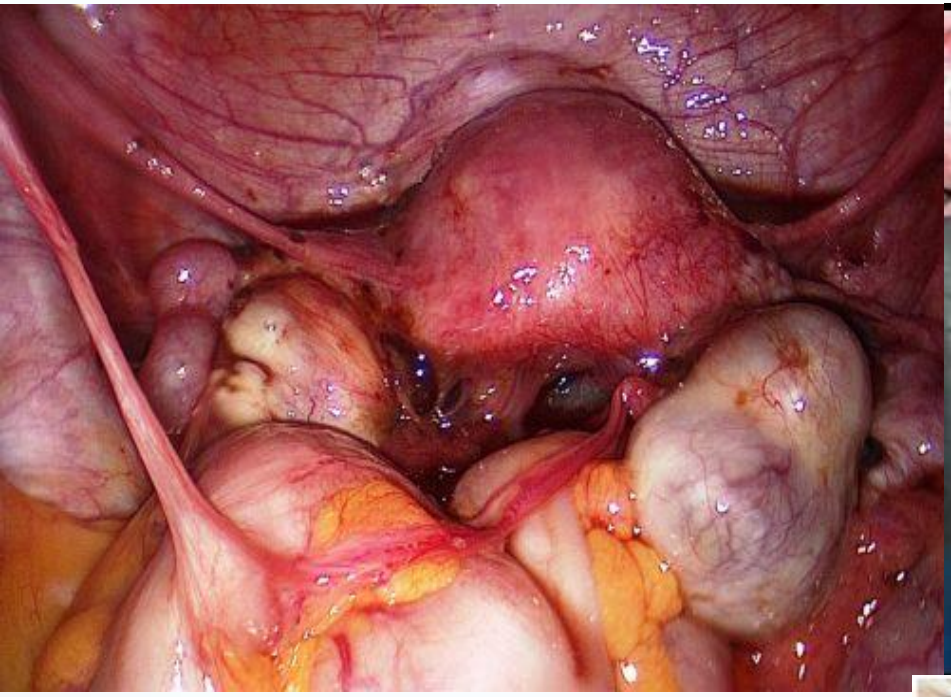

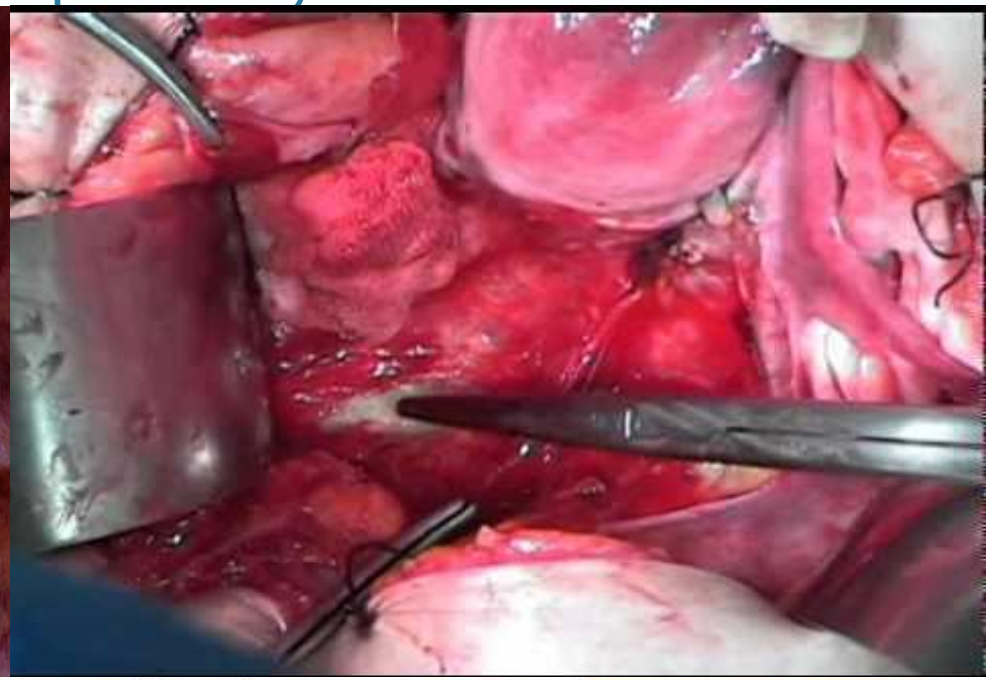

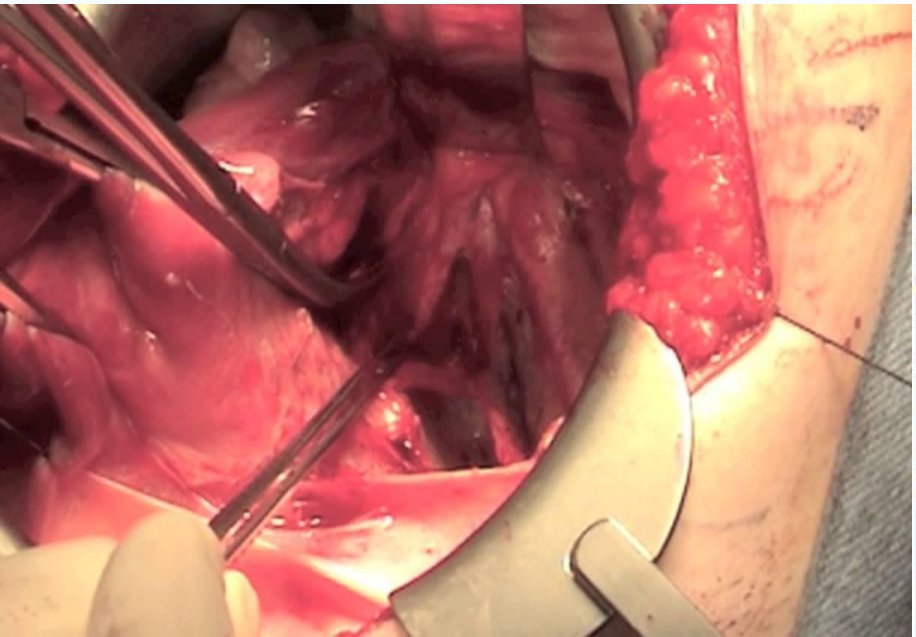

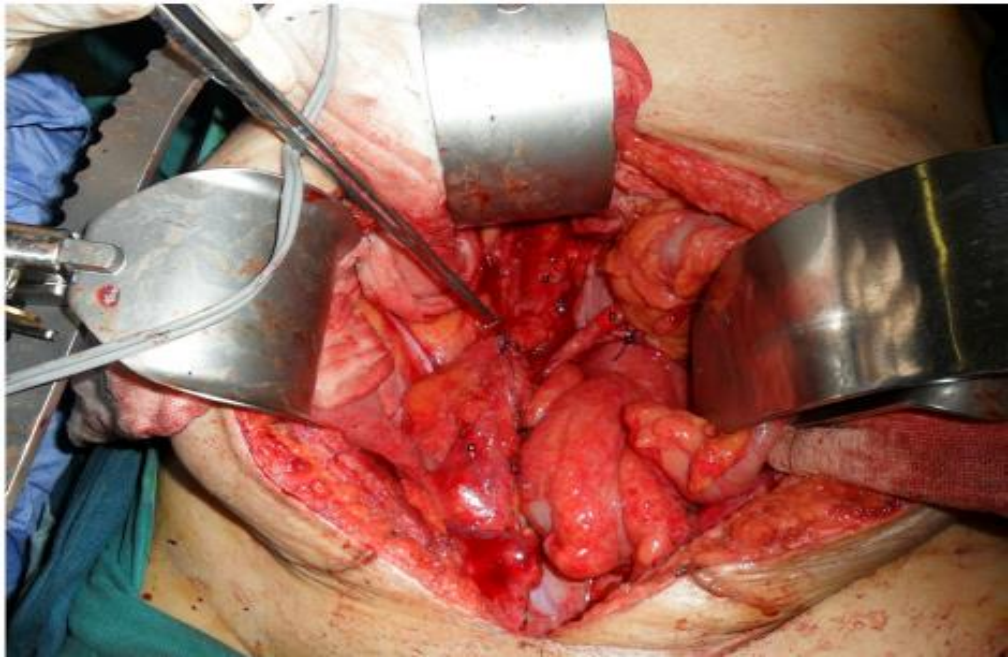

Laparoscopic ureteral reimplant for ureteral stricture

- International braz j urology
- **Int. braz j urol. vol.36 no.1 Rio de Janeiro Jan./Feb. 2010**
- **Rodrigo S. Q. Soares; Rubens A. de Abreu Jr; Jose E. F. Tavora**

Vascular anatomy

- Personal experience in Ovarian transplant research

Arterial Anastomosis

- Ovarian Artery 1-1.2 mm
- Uterine Artery 4-5 mm
- Internal Iliac Artery 10 mm
- Inferior Epigastric Artery 1.2 mm

Venous Anastomosis

- Ovarian Vein 4-5 mm
- Uterine Vein
- Inferior Epigastric Vein
- Internal Iliac Vein 10-15 mm

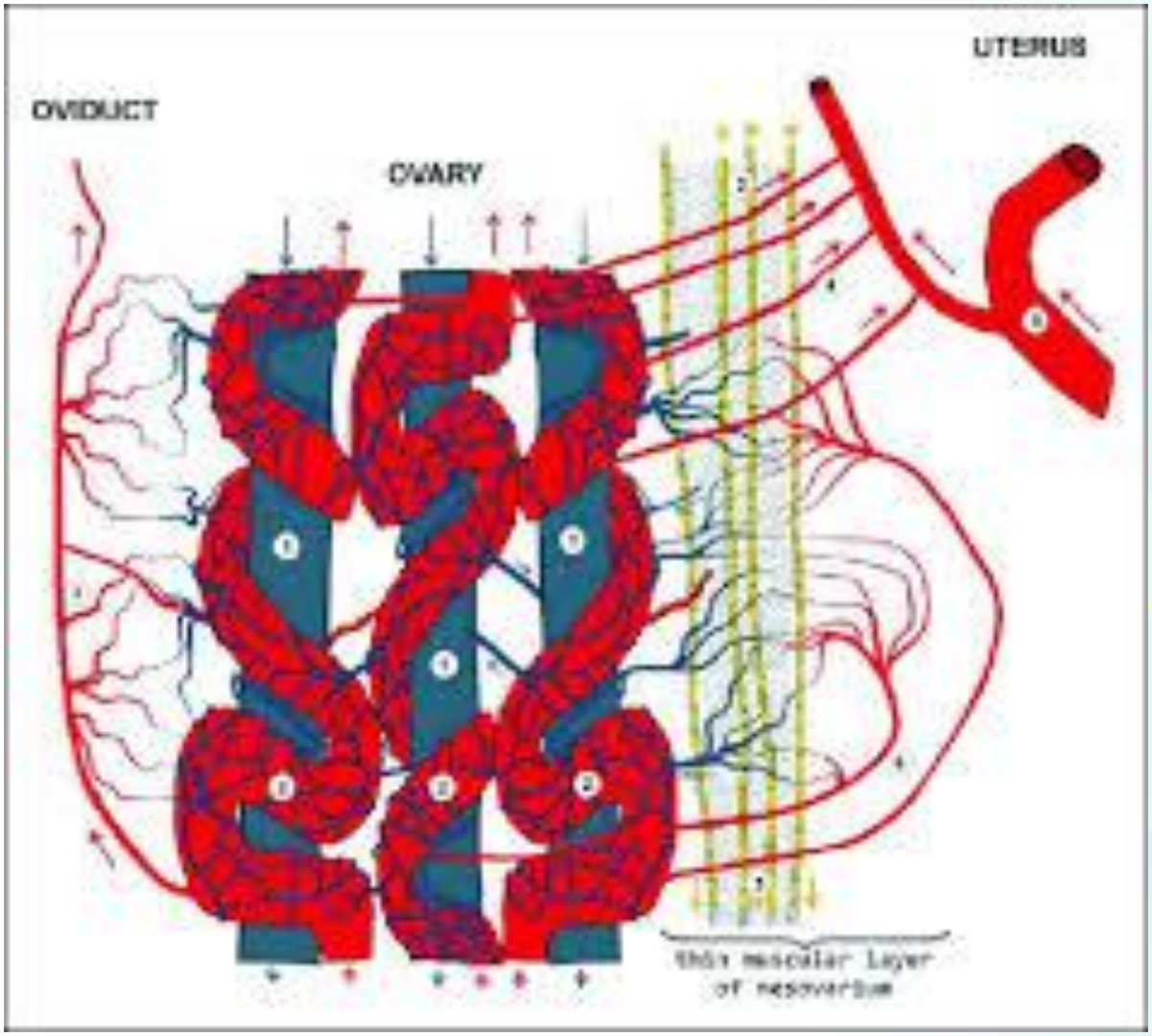

Prof. Dr. Pravin Mhatre

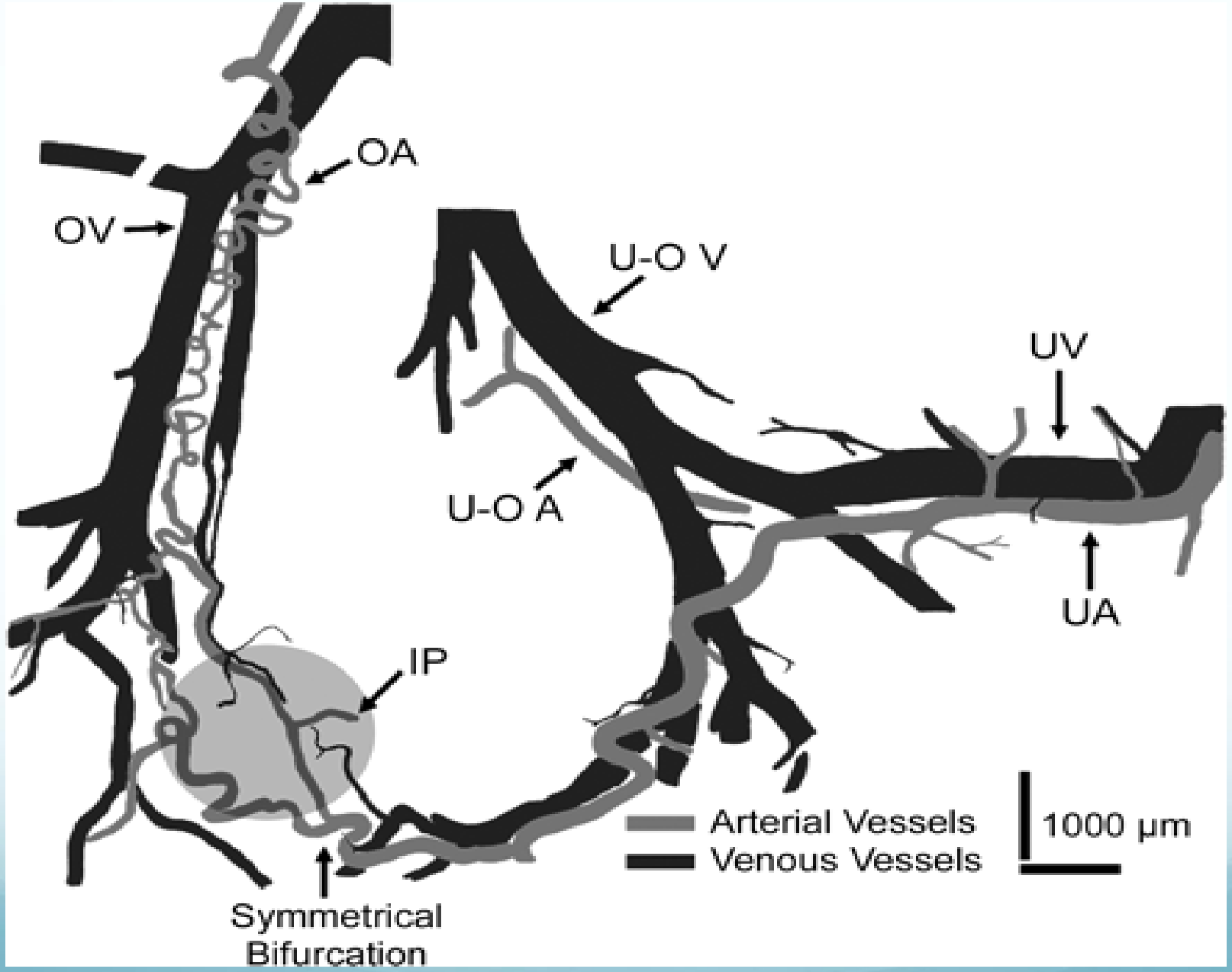
OA
OV
U-O V
UV
U-O A
UA
IP
Arterial Vessels
Venous Vessels
1000 µm
Symmetrical
Bifurcation

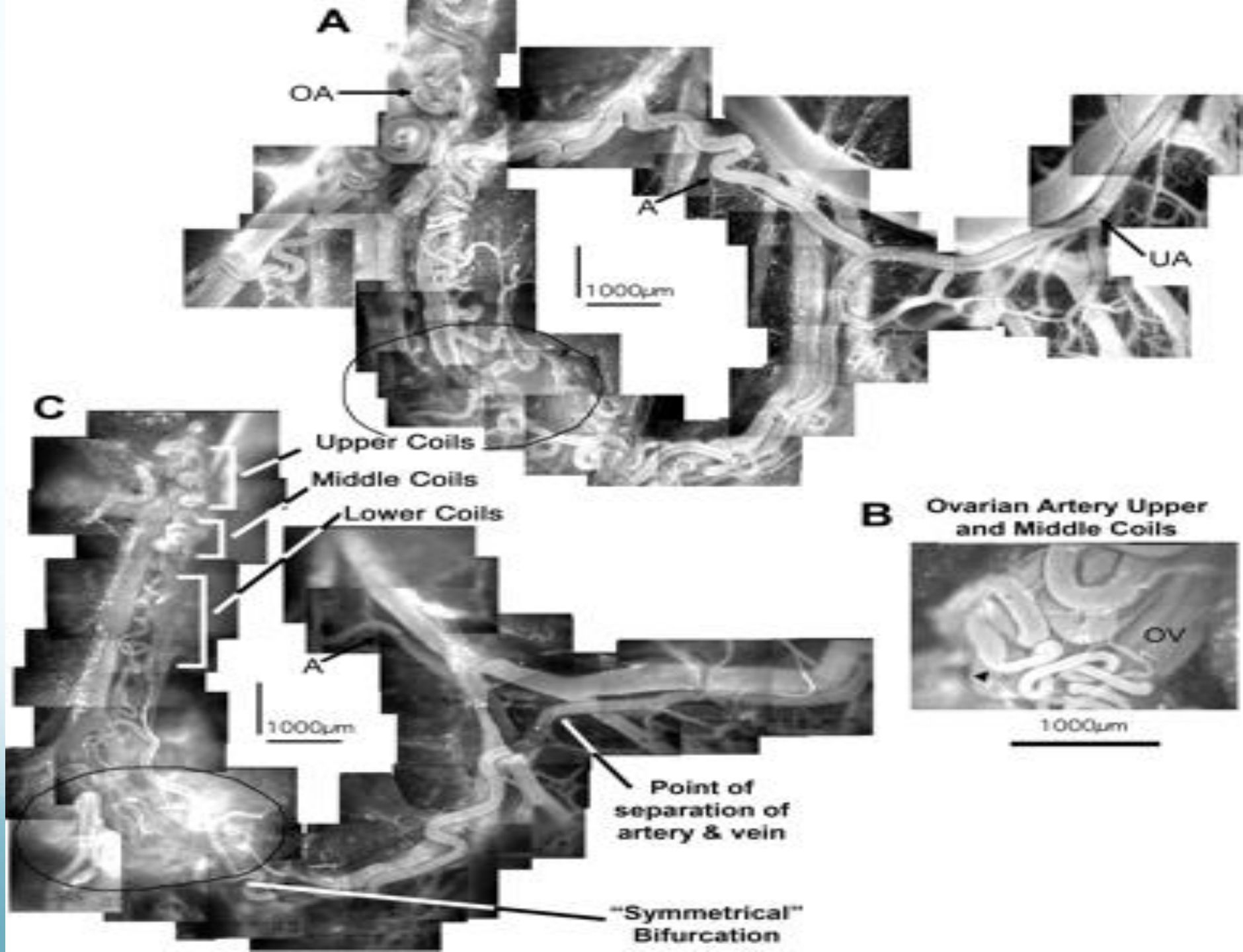
A
OA
A
1000µm
UA
Upper Coils
C
Middle Coils
Lower Coils
A
1000µm
Point of separation of artery & vein
"Symmetrical" Bifurcation
B
Ovarian Artery Upper and Middle Coils
OV
1000µm

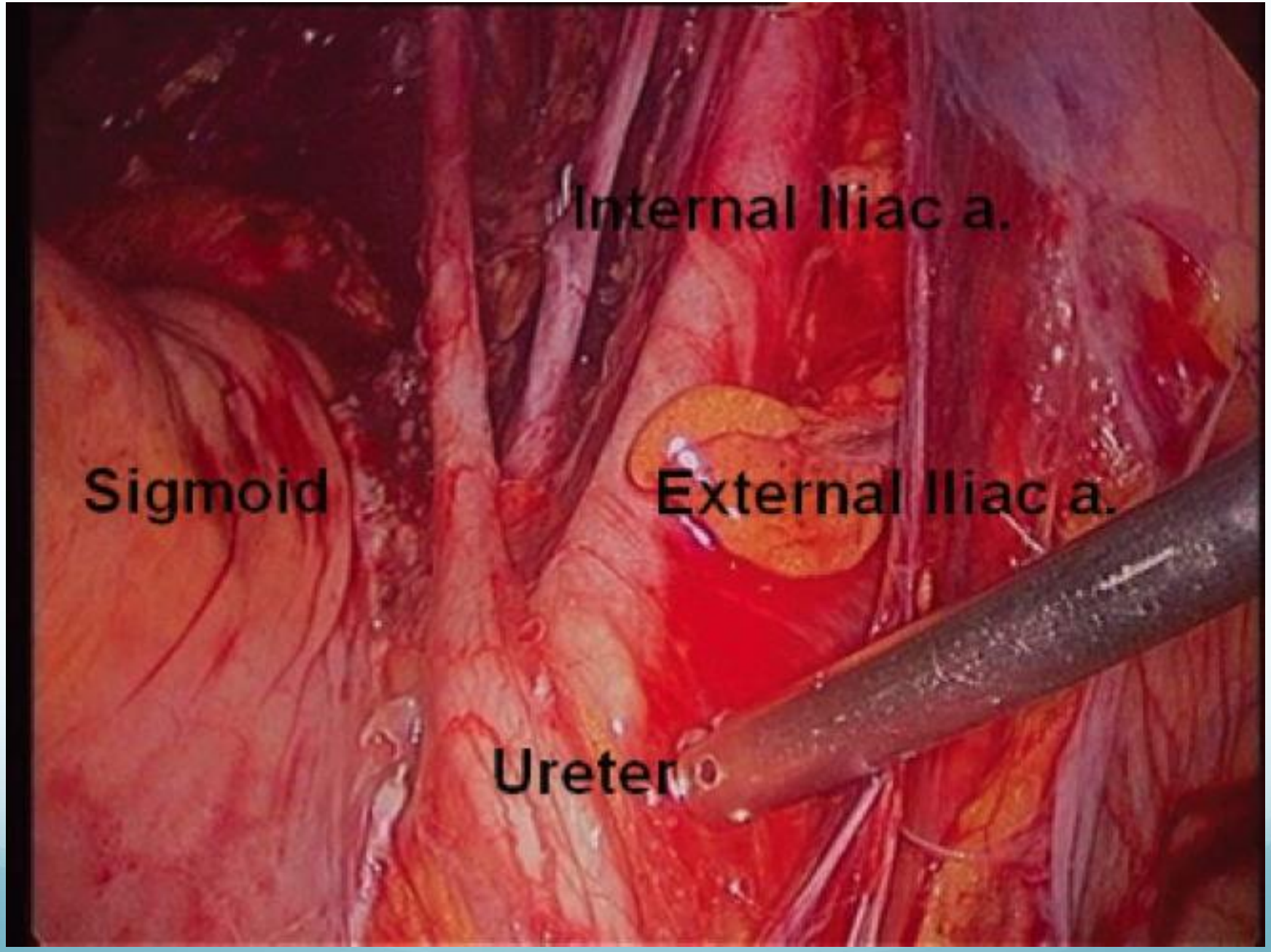
Internal Iliac a.
Sigmoid
External Iliac a.
Ureter

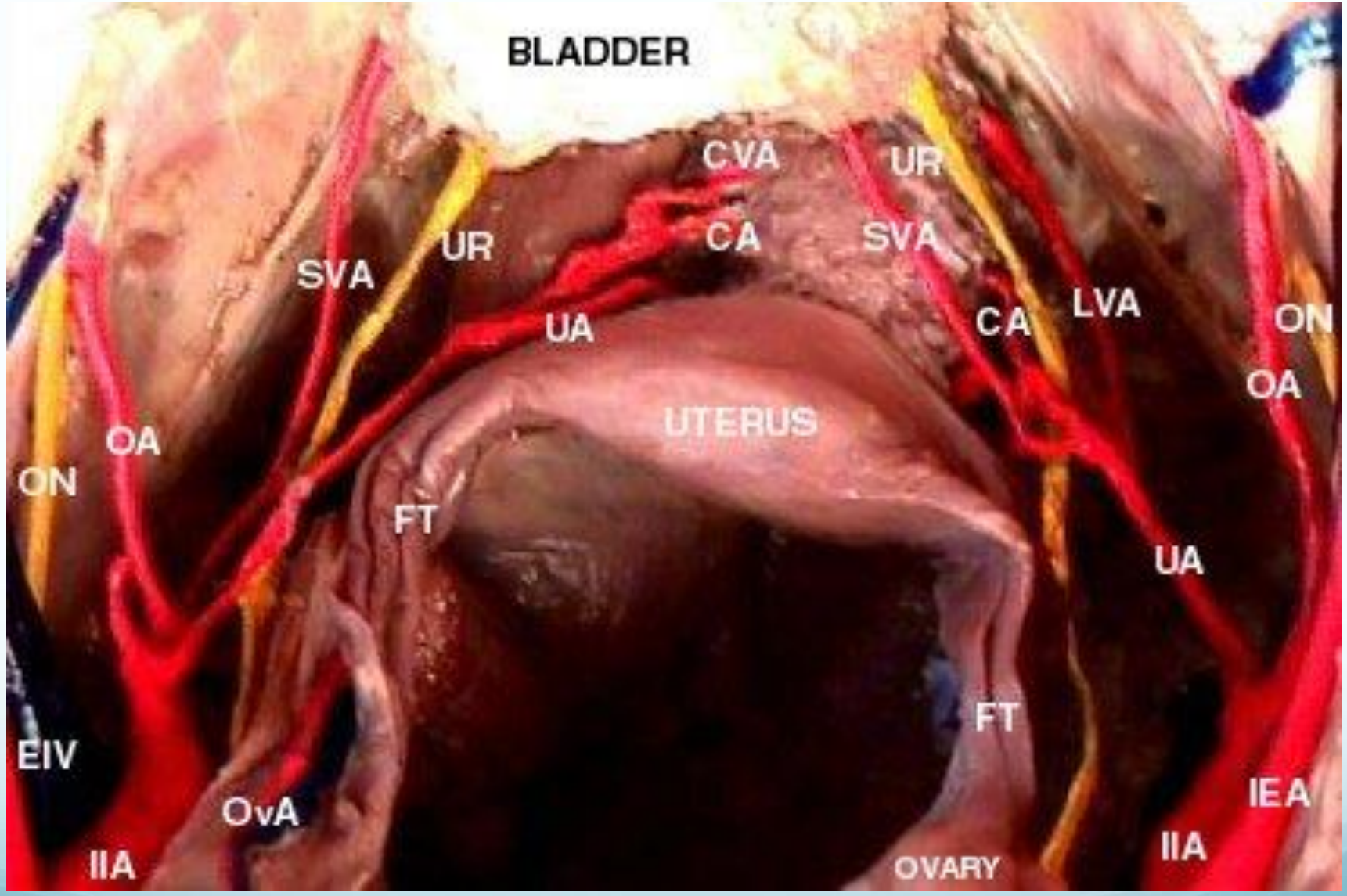

Teaching vascular Anatomy

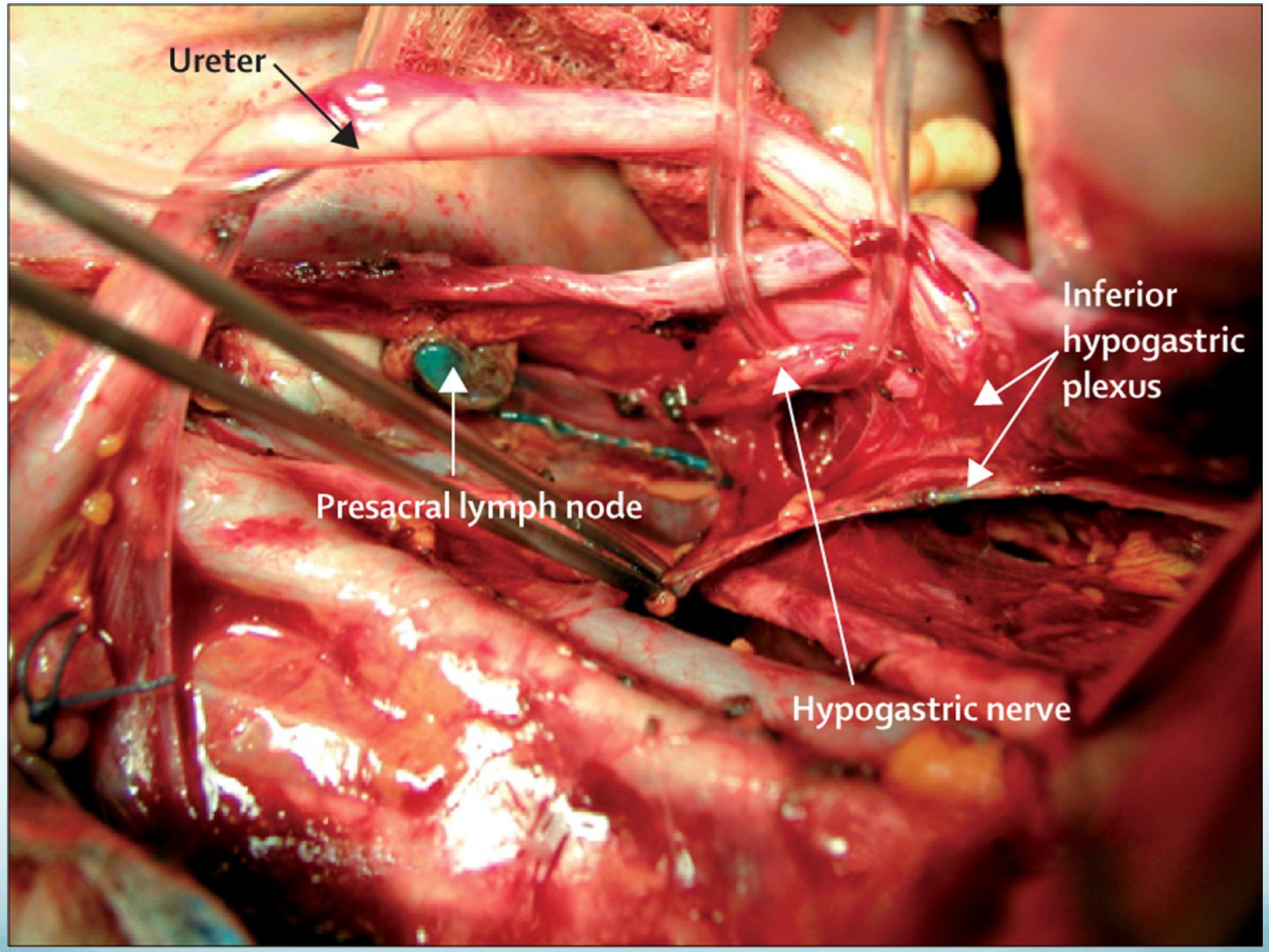

Teaching Neural Anatomy

Diagnosis and Treatment

- Endometriosis
- Tuberculosis
- Cancer staging – Ovarian / Cervical / Endometrial
- Tubal block
- PID

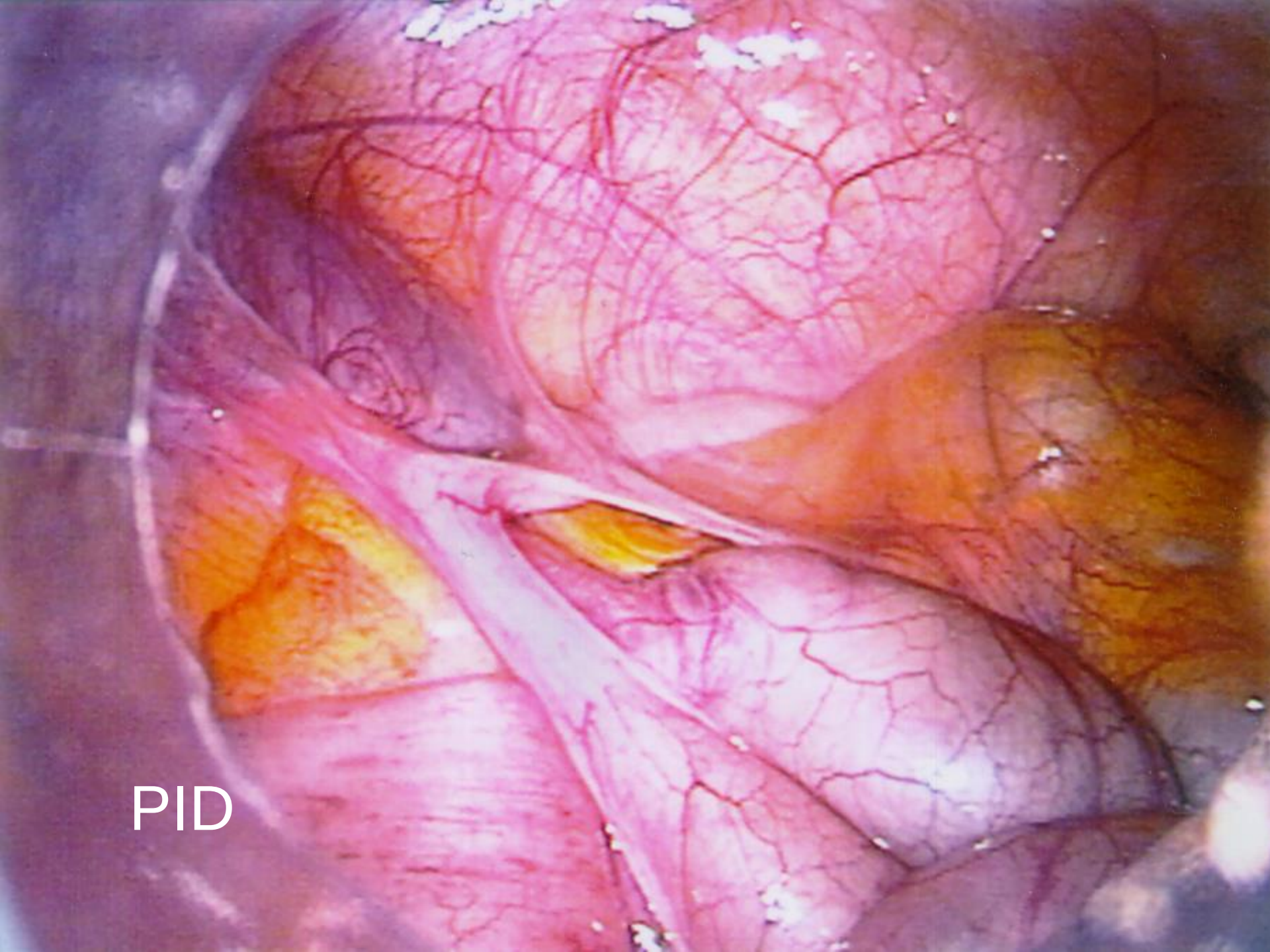
PID


Perihepatitis Fitz Hugs Curtis

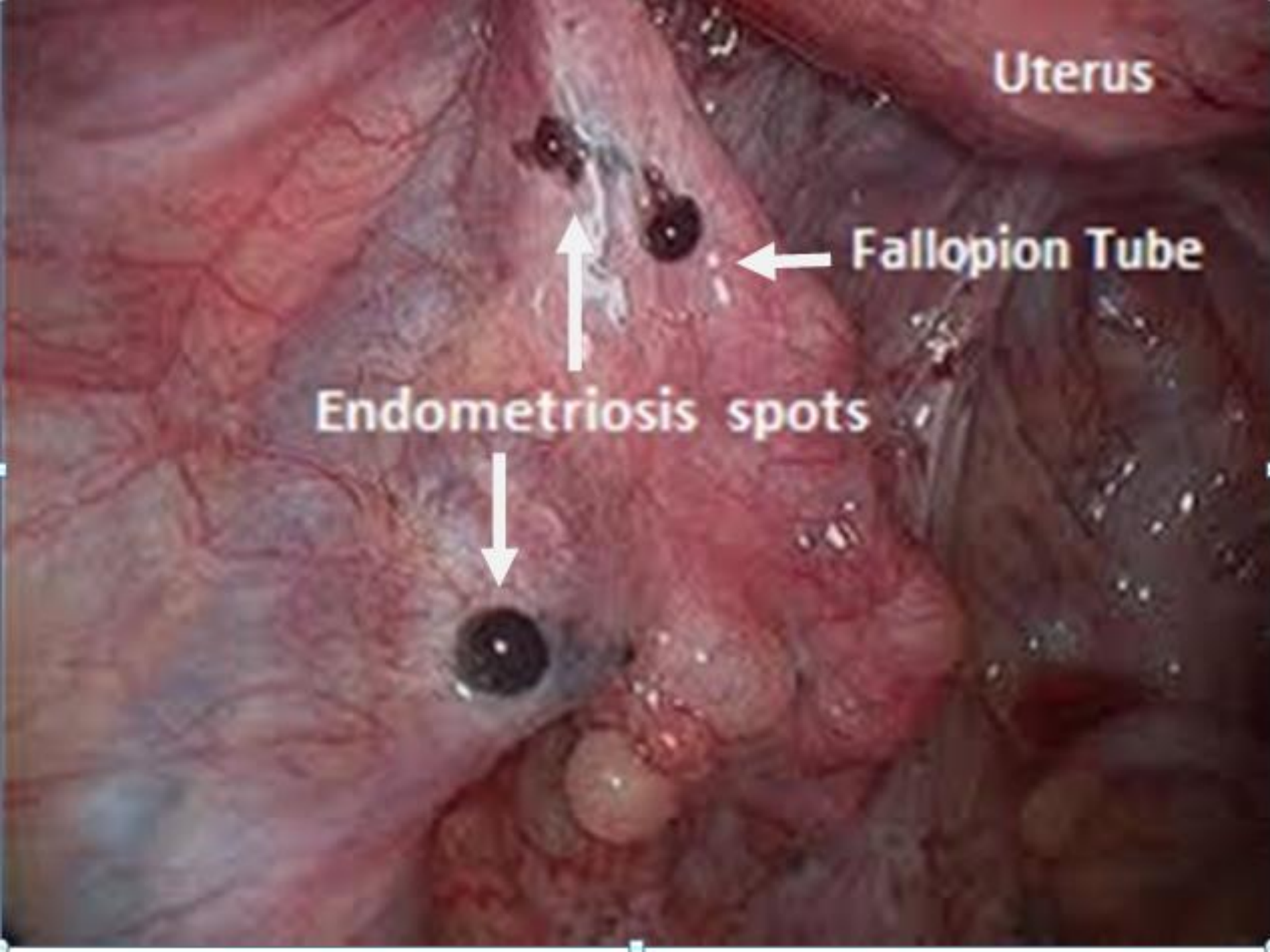
Uterus
Fallopion Tube
Endometriosis spots

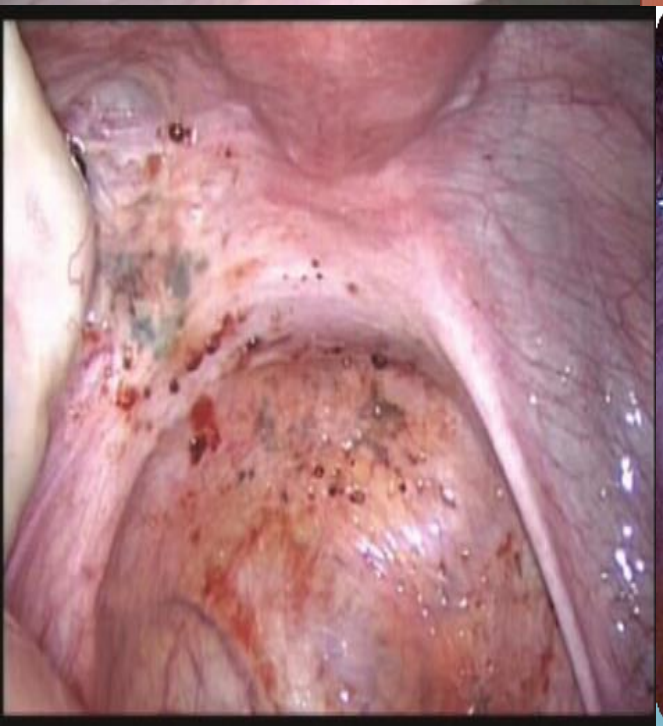

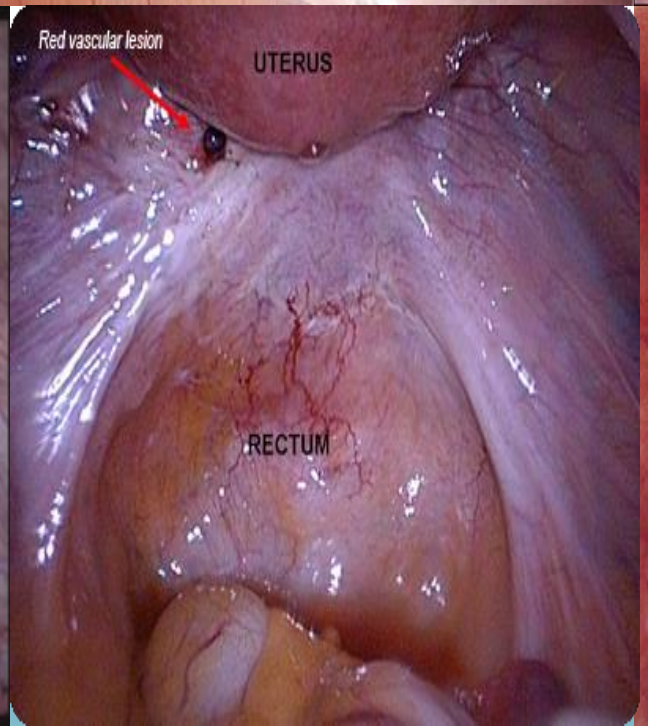
Red vascular lesion
UTERUS
RECTUM

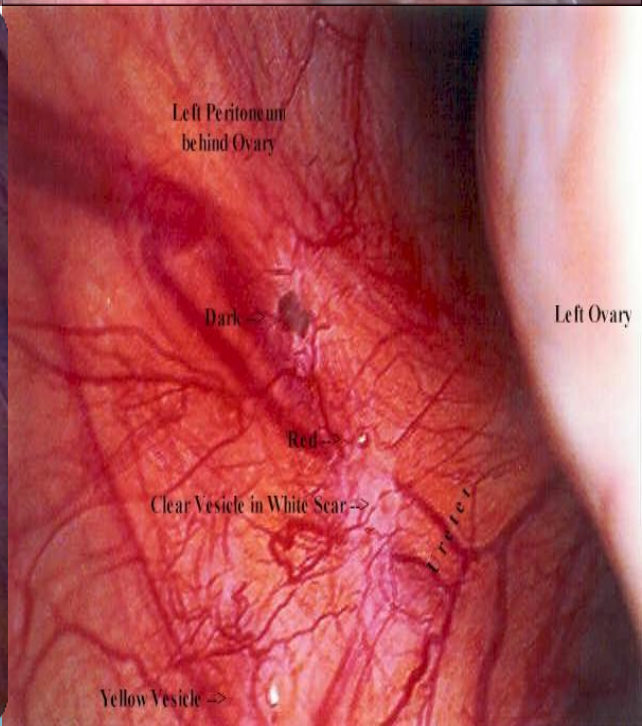
Left Peritoneum
behind Ovary
Dark ->
Left Ovary
Red ->
Clear Vesicle in White Scar ->
Yellow Vesicle ->

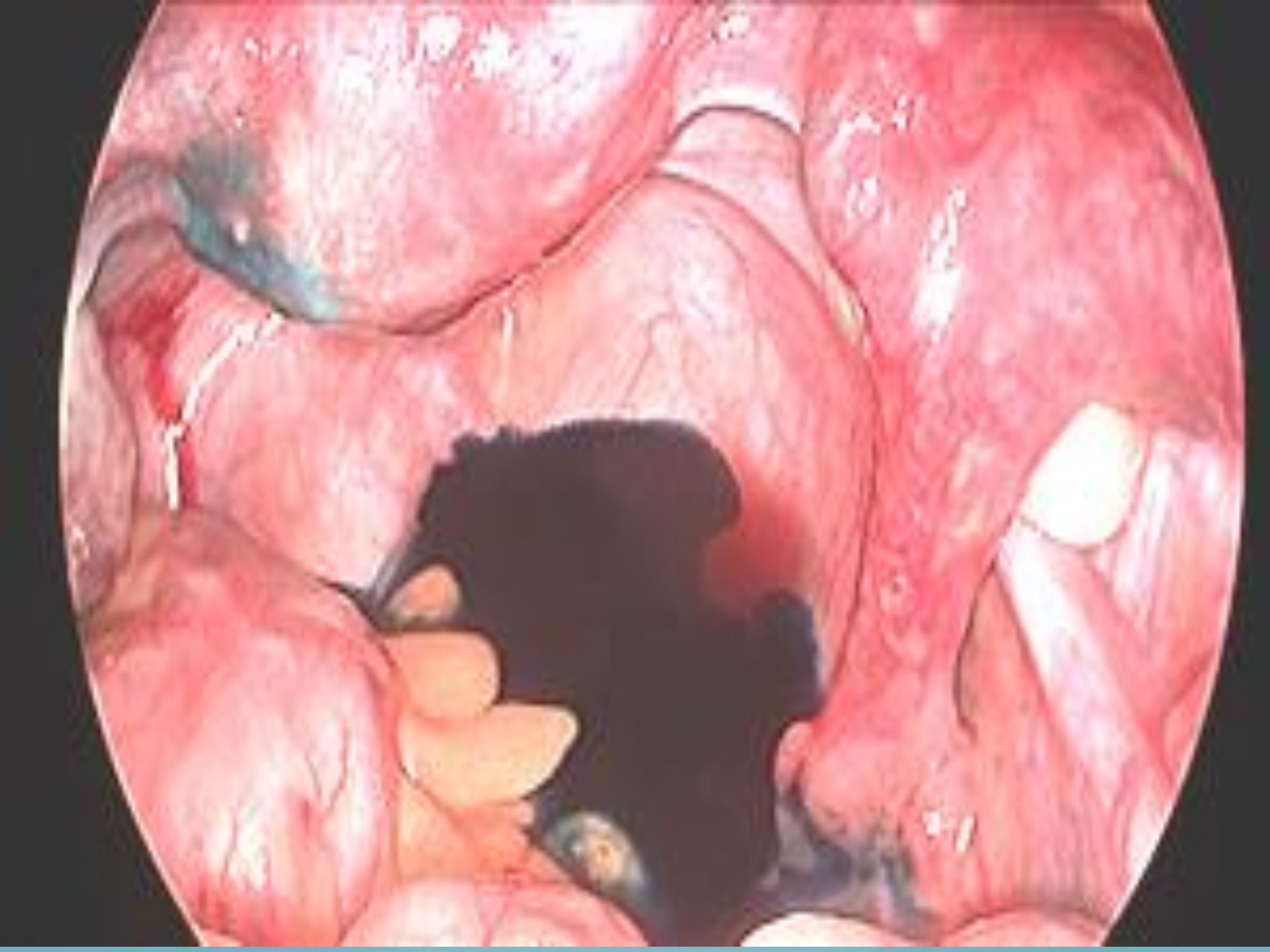

Tubal convolutions

Spigelian hernia

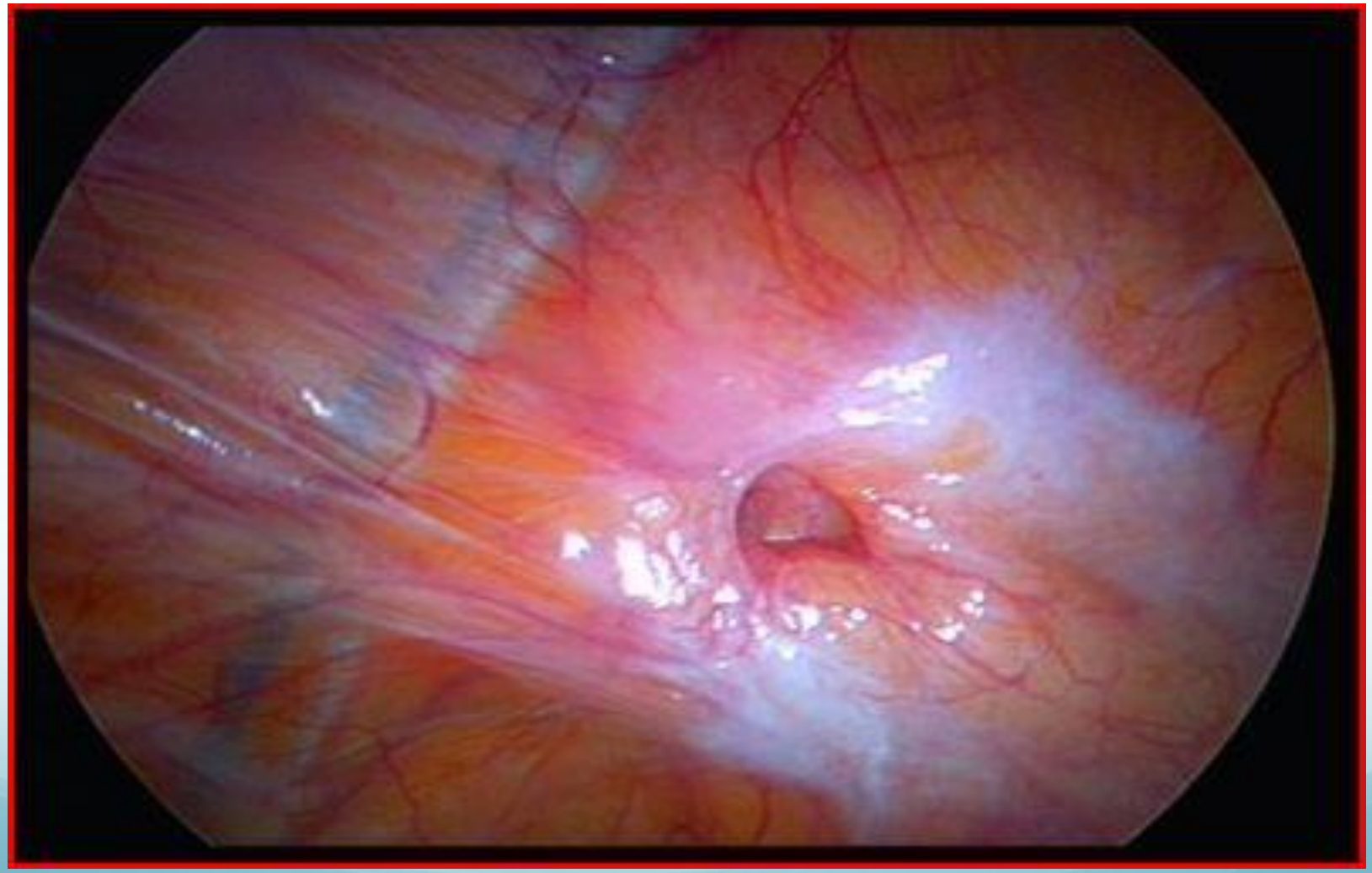

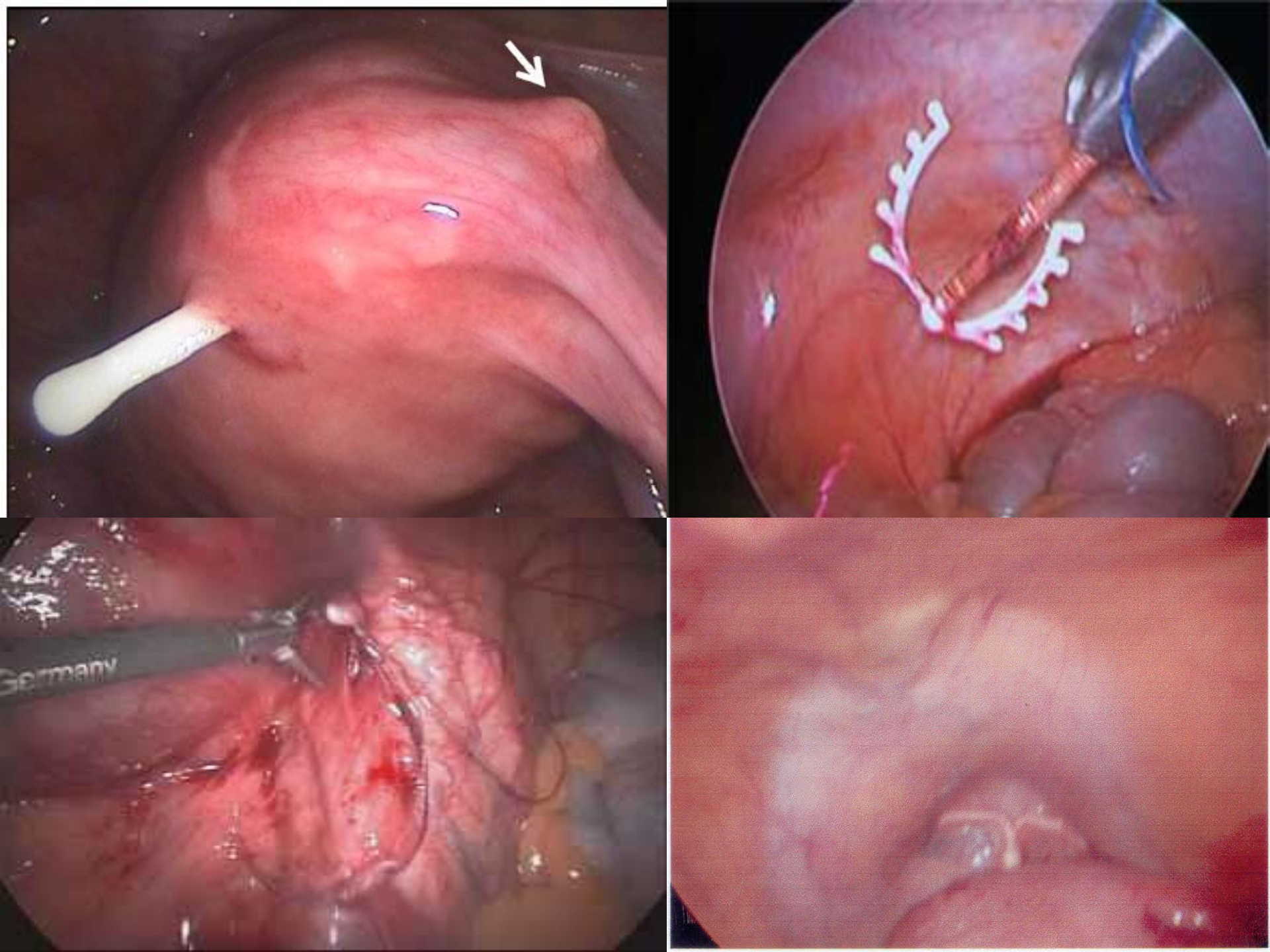
Germany

Treatment

- Tubal ligation / Tubal recanalisation
- Lost IUCD
- Ectopic pregnancy
- Endometriosis
- Pelvic Inflammatory disease
- Hysterectomy ?
- Myomectomy
- Radical hysterectomy

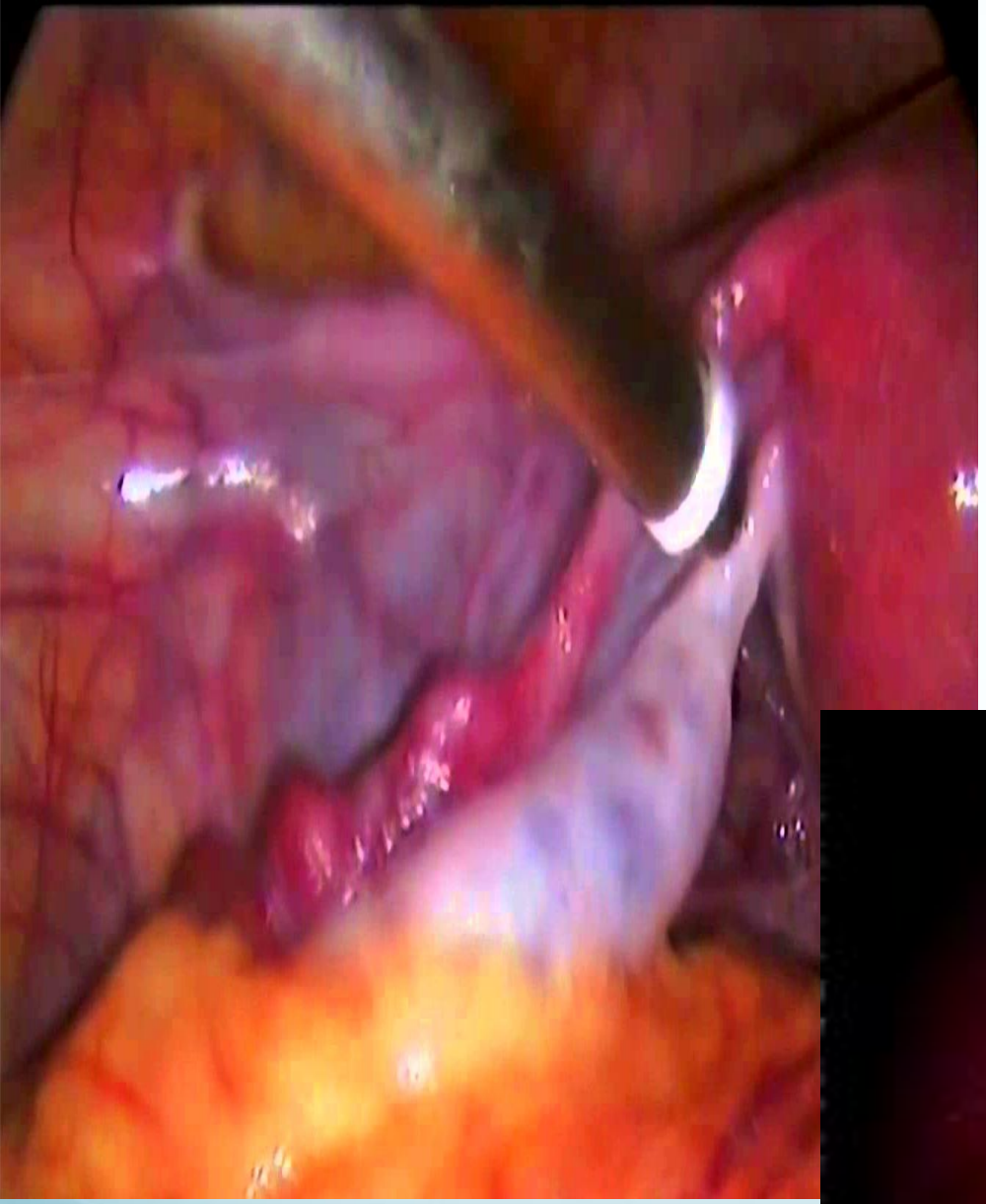

Tubal ligation
&
Reversal

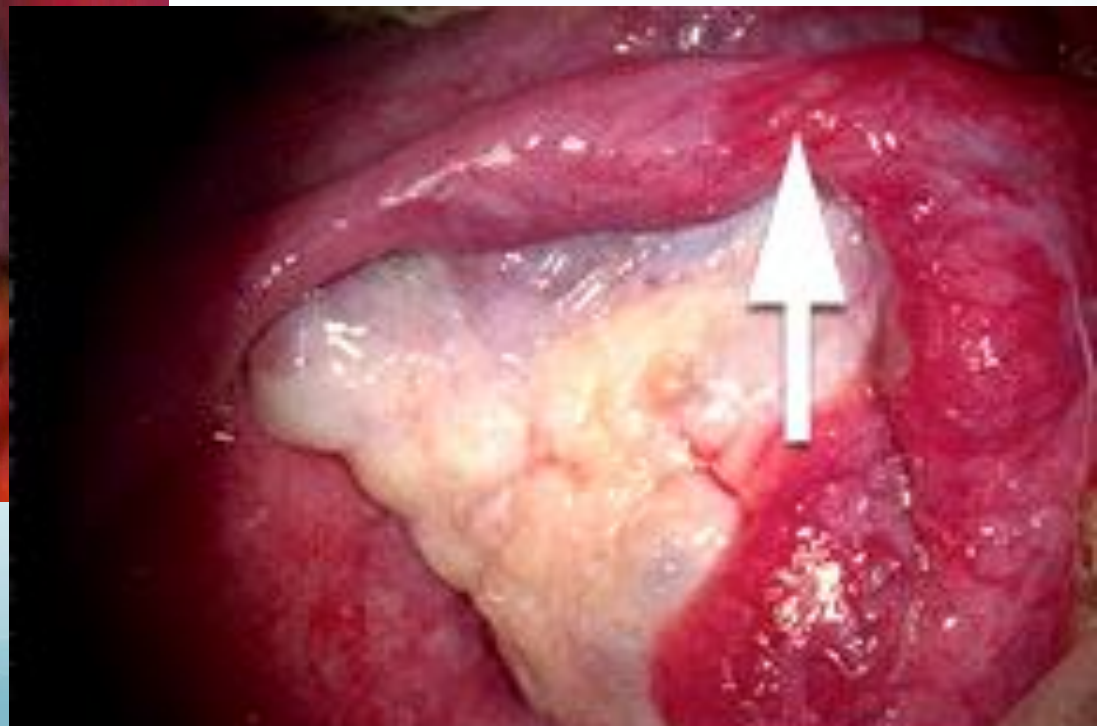

A comparative case-controlled study of laparoscopic vs. laparotomy management of ectopic pregnancy: an evaluation of reproductive performance after radical vs. conservative treatment of tubal ectopic pregnancy

Samina Tahseen & M. Wyldes

Pages 189-190 | Published online: 02 Jul 2009

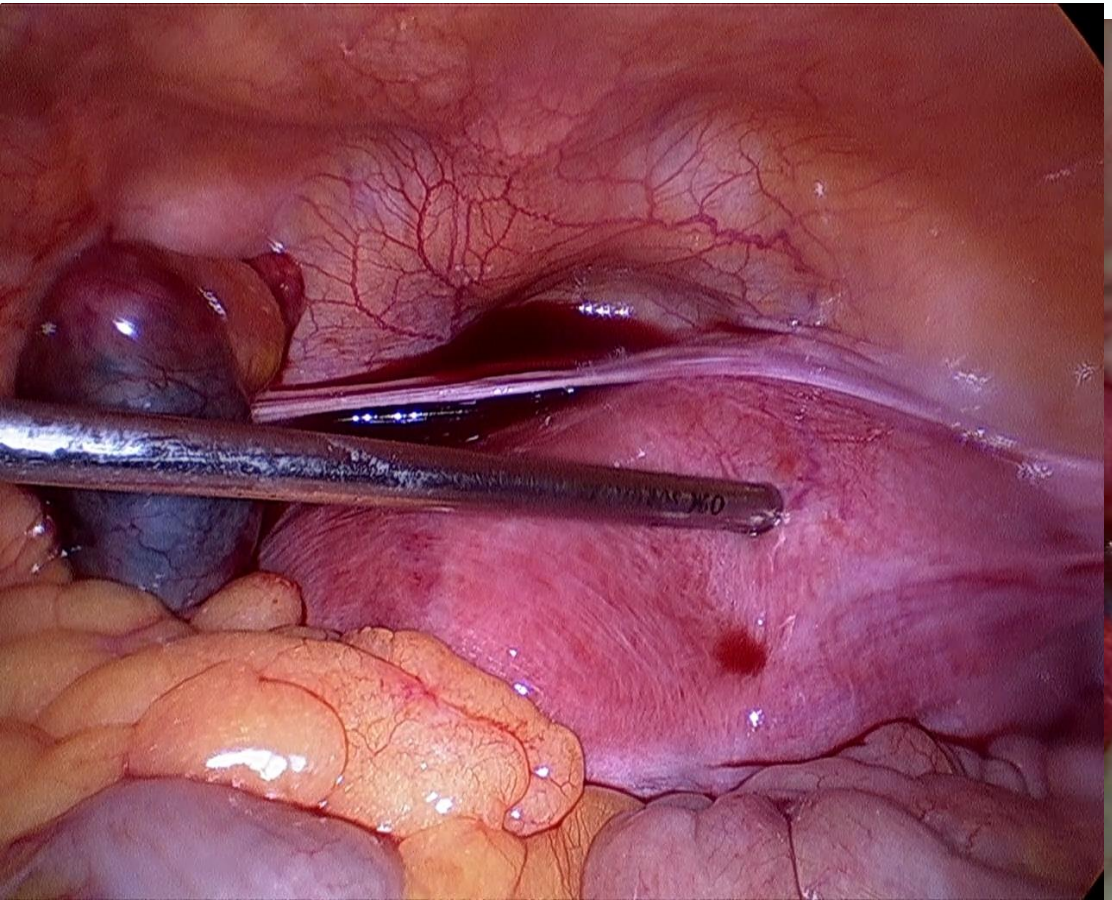

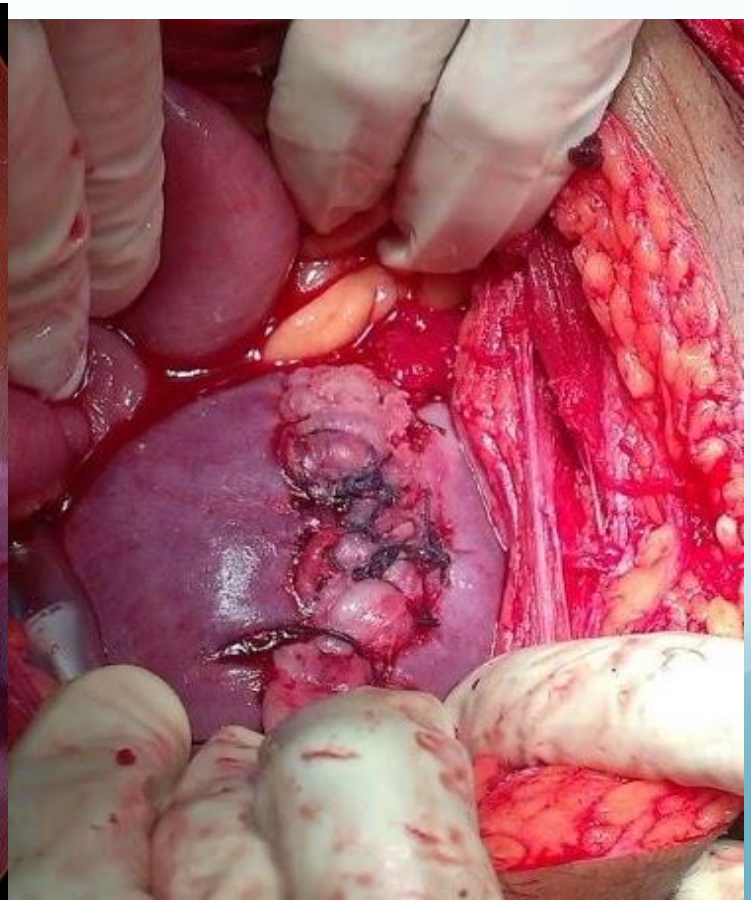

Ovarian drilling PCOD

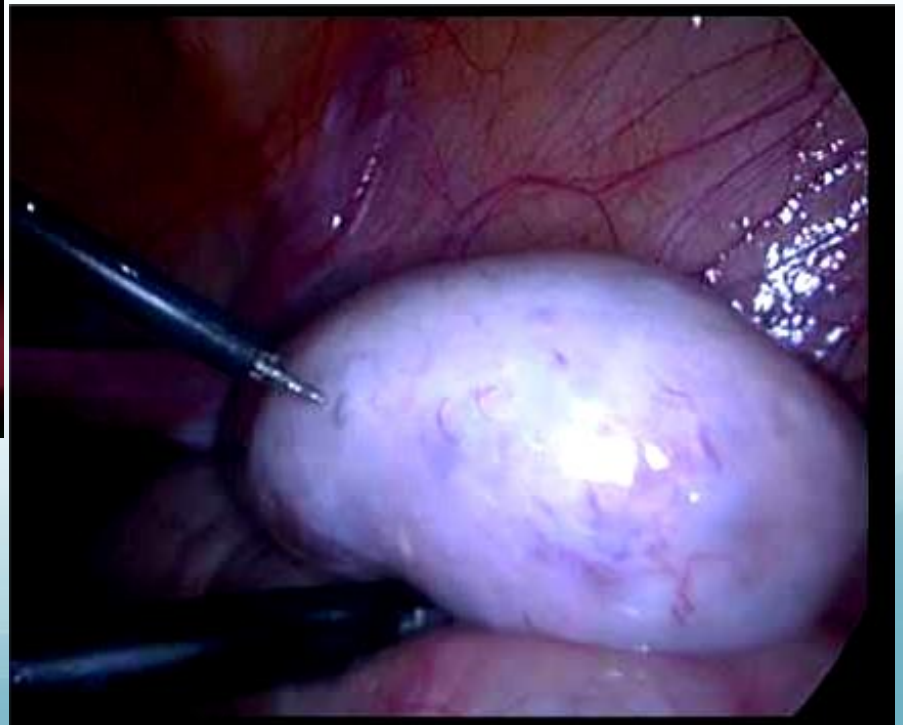

uterine perforation

- 90% of perforations are managed conservatively

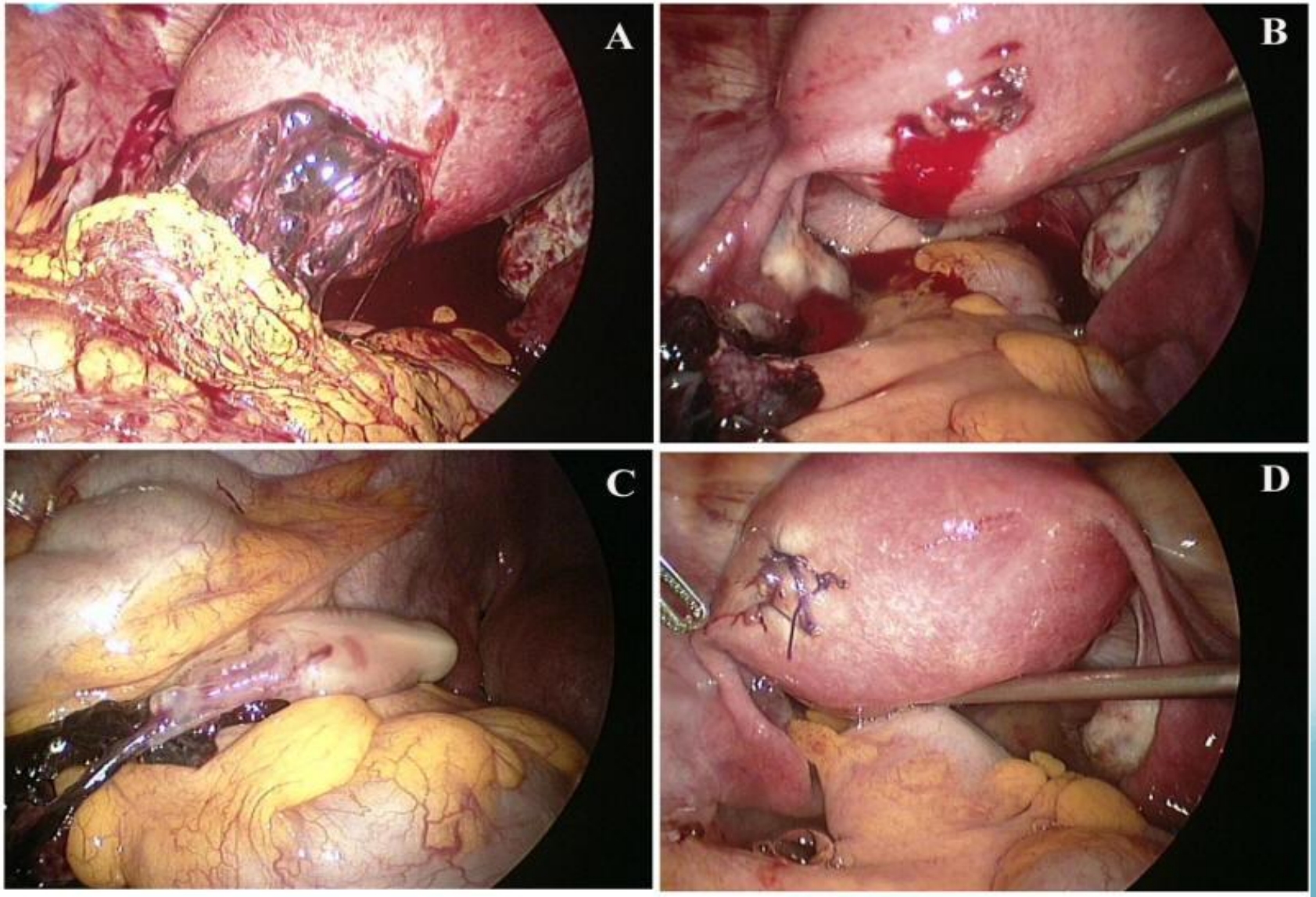

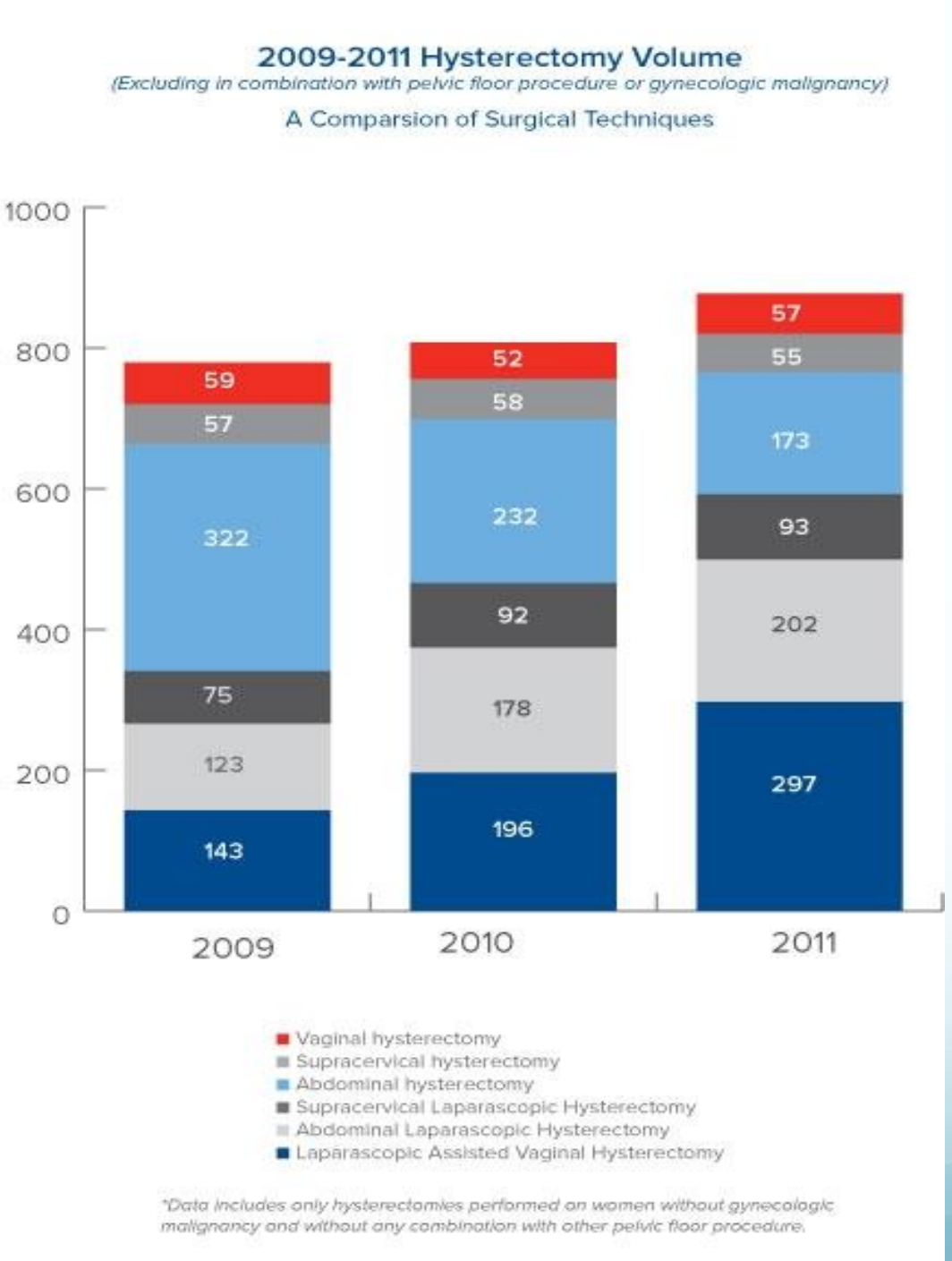

Hysterectomy

- GOG trial 2010-11
- Multiple randomized trials

- **Fertility and obstetric outcome after laparoscopic myomectomy of large myomata: a randomized comparison with abdominal myomectomy** R. Seracchioli
- Hum Reprod (2000) 15 (12): 2663-2668.
- pregnancy rate (55.9% after laparotomy, 53.6% after laparoscopy),
- abortion rate (12.1 versus 20%),
- preterm delivery (7.4 versus 5%)
- Caesarean section (77.8 versus 65%).
- No case of uterine rupture during pregnancy or labour was observed.

The Journal of the American Association of Gynecologic Laparoscopists
Volume 8, Issue 3, August 2001, Pages 348–352

Original Articles

Fertility Outcome after Tubal Anastomosis by Laparoscopy and Laparotomy http://www.sciencedirect.com/science/article/pii/S1074380405603295 - item1

Sun Hee Cha, M.D.[a],

- 81 Enrolled for reversal of sterilisation
- 76 analysed for fertility outcome

Laparoscopic – 37 patients
Laparotomy - 44

•Anastomosis was performed in two layers with four stitches using microsurgical technique

•Pregnancy rate 80%

•Laparoscopy- more operating time but less hosp. stay

Randomized Trial of Laparoscopically Assisted Versus Open Colorectal Resection for Endometriosis: Morbidity, Symptoms, Quality of Life, and Fertility

Daraï, Emile MD, PhD; Dubernard, Gil MD, PhD; Coutant, Charles MD; Frey, Catherine MD; Rouzier, Roman MD, PhD; Ballester, Marcos MD

Annals of Surgery:
June 2010 - Volume 251 - Issue 6 - pp 1018-1023

- **Comparison of laparoscopic versus conventional open surgical staging procedure for endometrial cancer**
- Tae Wook Kong,
- **Conclusion**
- Laparoscopic surgical staging operation is a safe and effective therapeutic procedure for management of endometrial cancer with an acceptable morbidity compared to the laparotomic approach, and is characterized by far less blood loss and shorter postoperative hospitalization.

Results of the First Randomized Prospective Study Evaluating Laparoscopy Versus Laparotomy for the Staging and Treatment of Endometrial Cancer			
Parameters	**Laparoscopy**	**Laparotomy**	**PValue**
No. of patients	37	33	–
Mean age	68.3	67.7	NS
Body Mass Index	2917	29.7	NS
Pelvic lymphadenectomy	25	24	NS
Pelvic lymph nodes (mean)	16.1±7.6	15.4±7.6	NS
Paraaortic lymph nodes (mean, 20 patients)	9.6±4.7	8.4±6.4	NS
Operative time	176.4±85.4	166.1±61	NS
Estimated blood lost	229.2±190.2	594.2±629.9	0.003
Transfusion	1	11	0.005
Length of stay	8.6±2.7	11.7±3.8	<0.001
Complications	11 (29.7%)	13 (39.3%)	NS
Follow up (months)	16.5 (2–43)	21.6 (2–48)	–
Recurrences	1	2	NS
Recurrence related death	1	1	NS
Recurrence-free survival	97.3%	93.3%	NS
Overall survival	83.9%	90.9%	NS

Table 4. Results of the First Randomized Prospective Study Evaluating Laparoscopy Versus Laparotomy for the Staging and Treatment of Endometrial Cancer Adapted From Malur et al.[54]

GOG trial: laparotomy vs. laparoscopy

- Laparoscopic surgical staging for uterine cancer is feasible and safe in terms of short-term outcomes (2010)
- Fewer complications and shorter hospital stays
- Potential for a small increased risk of cancer recurrence with laparoscopy versus laparotomy
- 5-year overall survival being almost identical in both arms at 89.8% (2012)

Walker JL, Piedmonte MR, Spirtos NM, et al.
J Clin Oncol 2012;30:695-700

Incisional hernias after major laparoscopic gynecologic procedures

- American Journal of Obstetrics and Gynecology
- Volume 168, Issue 5, May 1993, Pages 1493-1495

-

- Nicholas Kadar

Compare the Wounds

(Smaller Wounds, Fewer Problems, Same Results)

Open Surgery

Laparoscopic Surgery

Vaginoplasty
Mullerian Anomalies

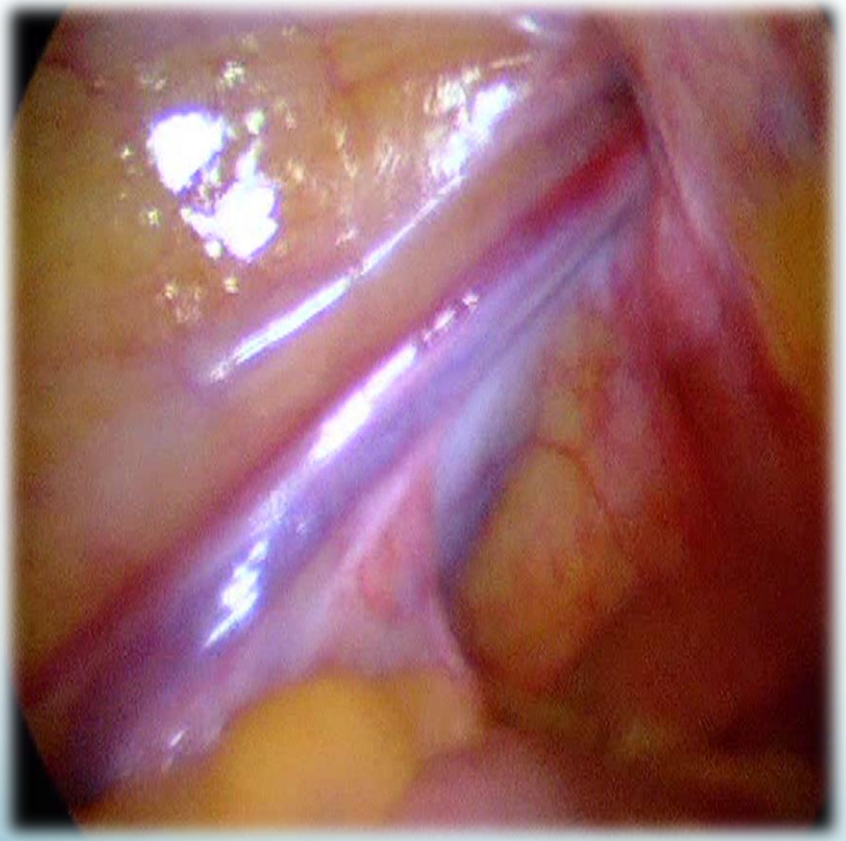

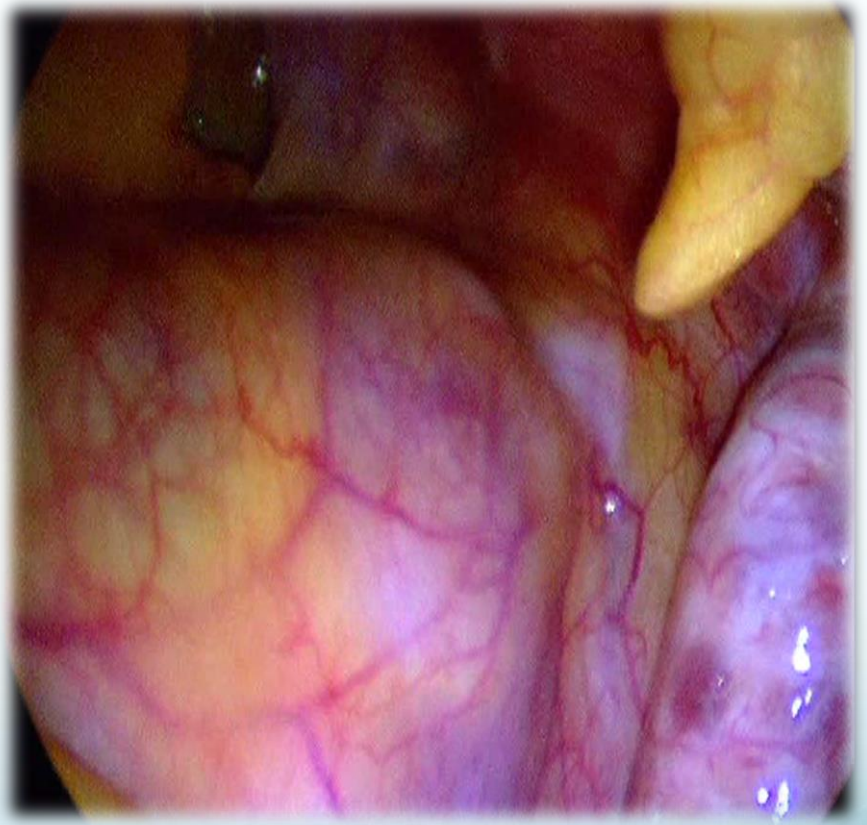

Double ureter and Fused pelvic kidney


Vaginoplasty
Research
Colon
vaginoplasty

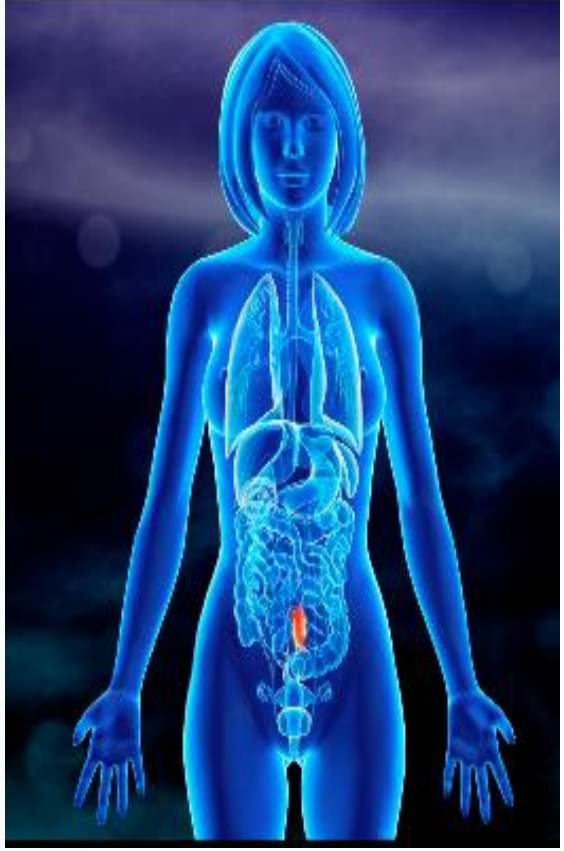


Ileal Vaginoplasty


B

Skin

Amnion

Vaginoplasty

New Vaginoplasty Technique Laparoscopic peritoneoplasty
The only technique creating normal Vagina

Adhesion formation

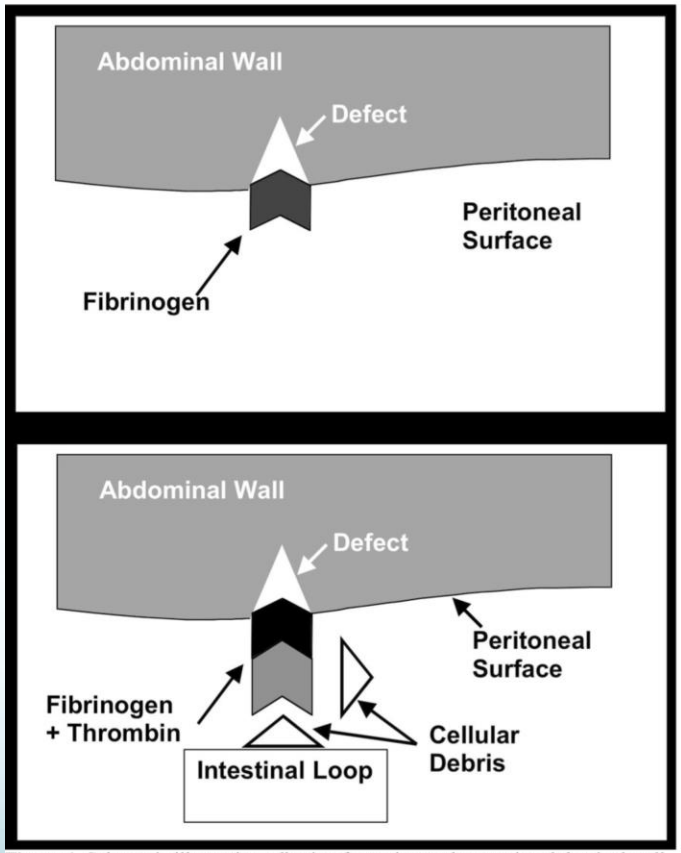

Figure 1. Schematic illustrating adhesion formation to the anterior abdominal wall.

Peritoneum damage EM

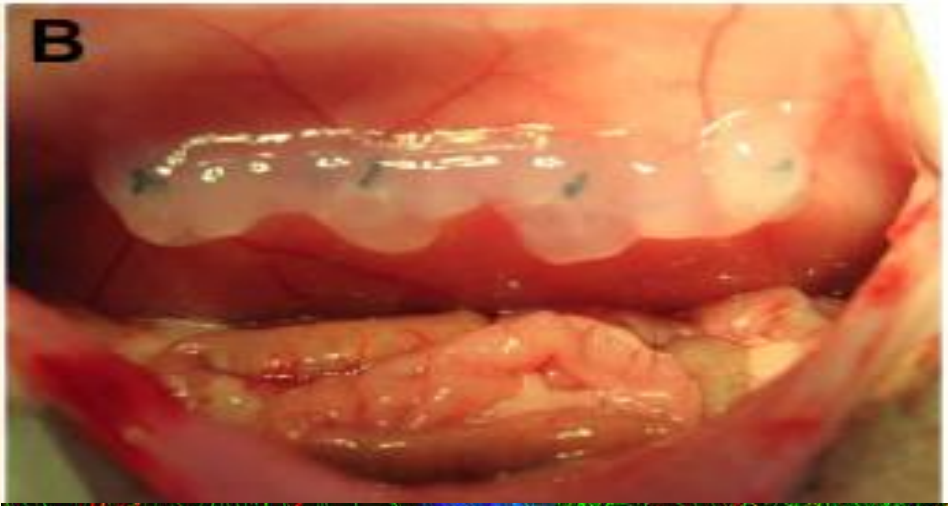

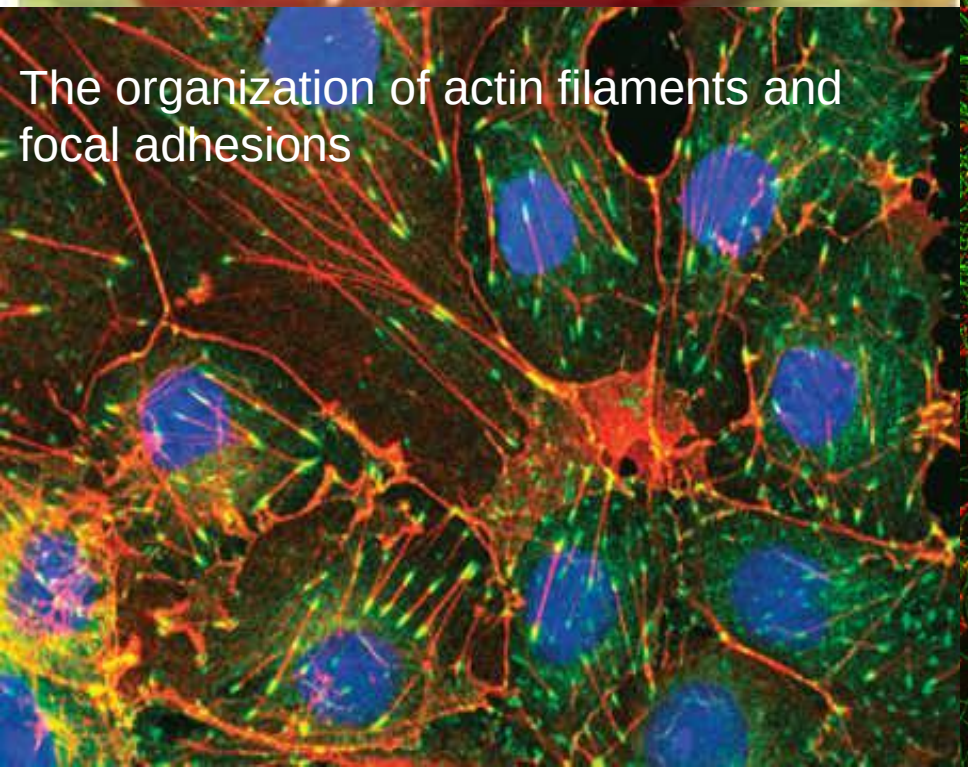

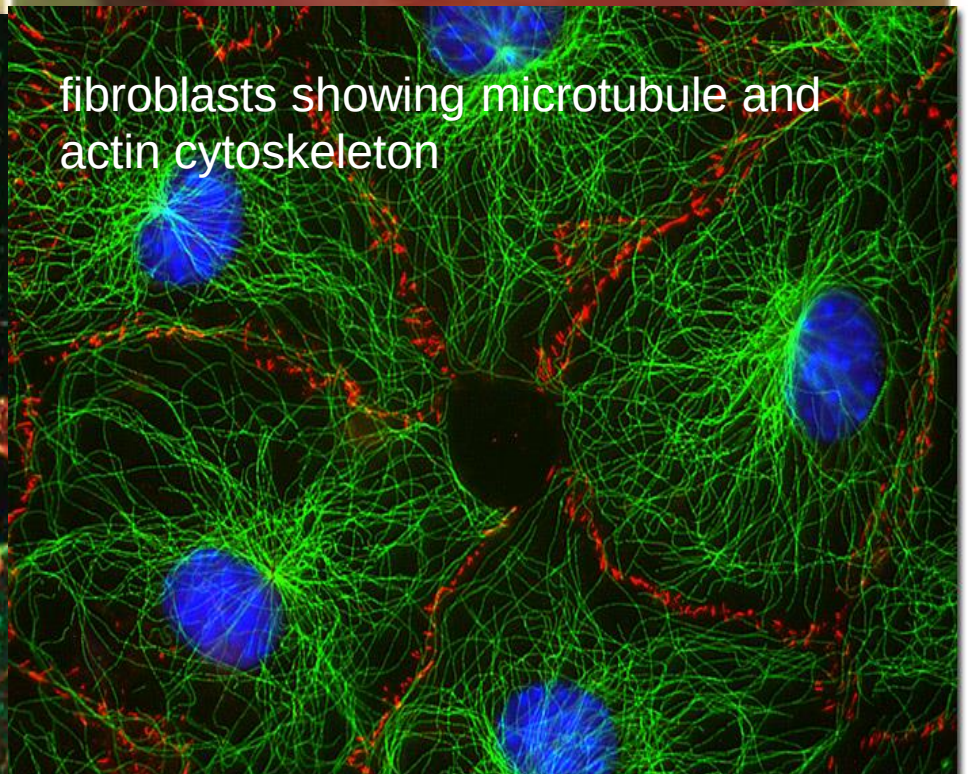

Prevalence of Adhesions Following Surgical Procedures

- >90% of laparotomies result in adhesion formation[a]
- Gastrointestinal: 60%-70%[b]
- Urologic: 22%[c]
- Gynecologic: 51%[c]
  - Especially myomectomy
  - Intra-uterine adhesions are also common (up to 95%)
- Cesarean delivery: 90%[d]

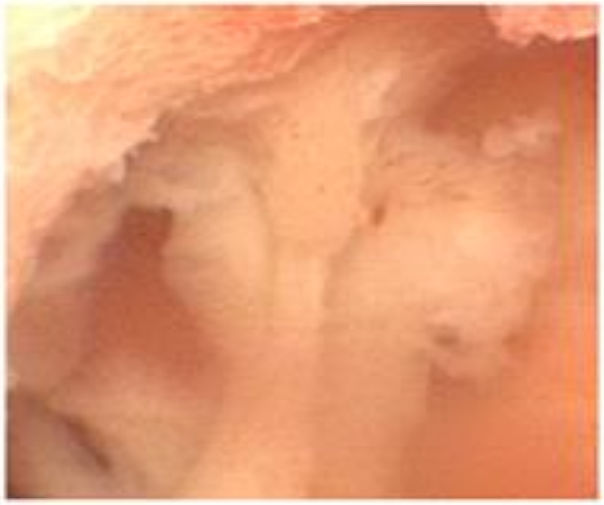

Intrauterine adhesion band
Image courtesy of G. Wright Bates Jr, MD

a. Menzies D, et al. *Ann R Coll Surg Engl*. 1990;72:60-63; b. Diamond MP, et al. *Hum Reprod Update*. 2001;7:567-576; c. Okabayashi K, et al. *Surgery Today*. 2014;44:405-420; d. Morales A, et al. *Am J Obstet Gynecol*. 2007;196:461-466.

Adhesion Prevention Strategies

- Surgical technique
  - Limiting tissue injury and ischemia
  - Gentle tissue handling
- Meticulous hemostasis
  - Lacks randomized trials
- Reperitonealization?
- Laparoscopy vs laparotomy
- Poor results with lysis of adhesions
  - Especially to restore fertility

Anterior abdominal wall adhesion
Image courtesy of G. Wright Bates Jr, MD

Prevalence of Adhesions Following Laparoscopic Procedures

- More than half of operative gynecologic laparoscopies develop[a]
  - De novo adhesions: 82% at second look
  - 43% of adhesions reformed
- Laparoscopic transperitoneal urologic surgery
  - 22% developed intraabdominal adhesions[b]

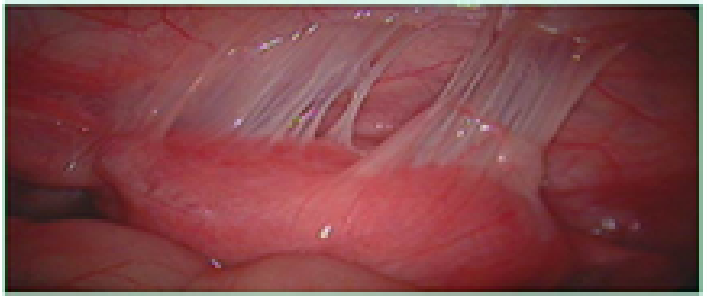

Uterine adhesion
Image courtesy of G. Wright Bates Jr, MD

a. Parker JD, et al. *Fertil Steril*. 2005;84:1457-1461; b. Pattaras JR, et al. *Urology*. 2002;59:37-41.

Etiology of Adhesion Formation

- Ischemia[a]
- Tissue manipulation[b]
- Abrasion[b]
- Suturing[b]
- Infection[b]
- Peritoneal closure[c]

Image courtesy of G. Wright Bates Jr, MD

Surgery always has the potential to cause adhesions.

a. Awonuga AO, et al. *Reprod Sci*. 2011;18:1166-1185; b. Diamond MP, et al. *Hum Reprod Update*. 2001;7:567-576; c. Lyell DJ, et al. *Am J Obstet Gynecol*. 2012;206:515.e1-e5.

Healing of peritoneum

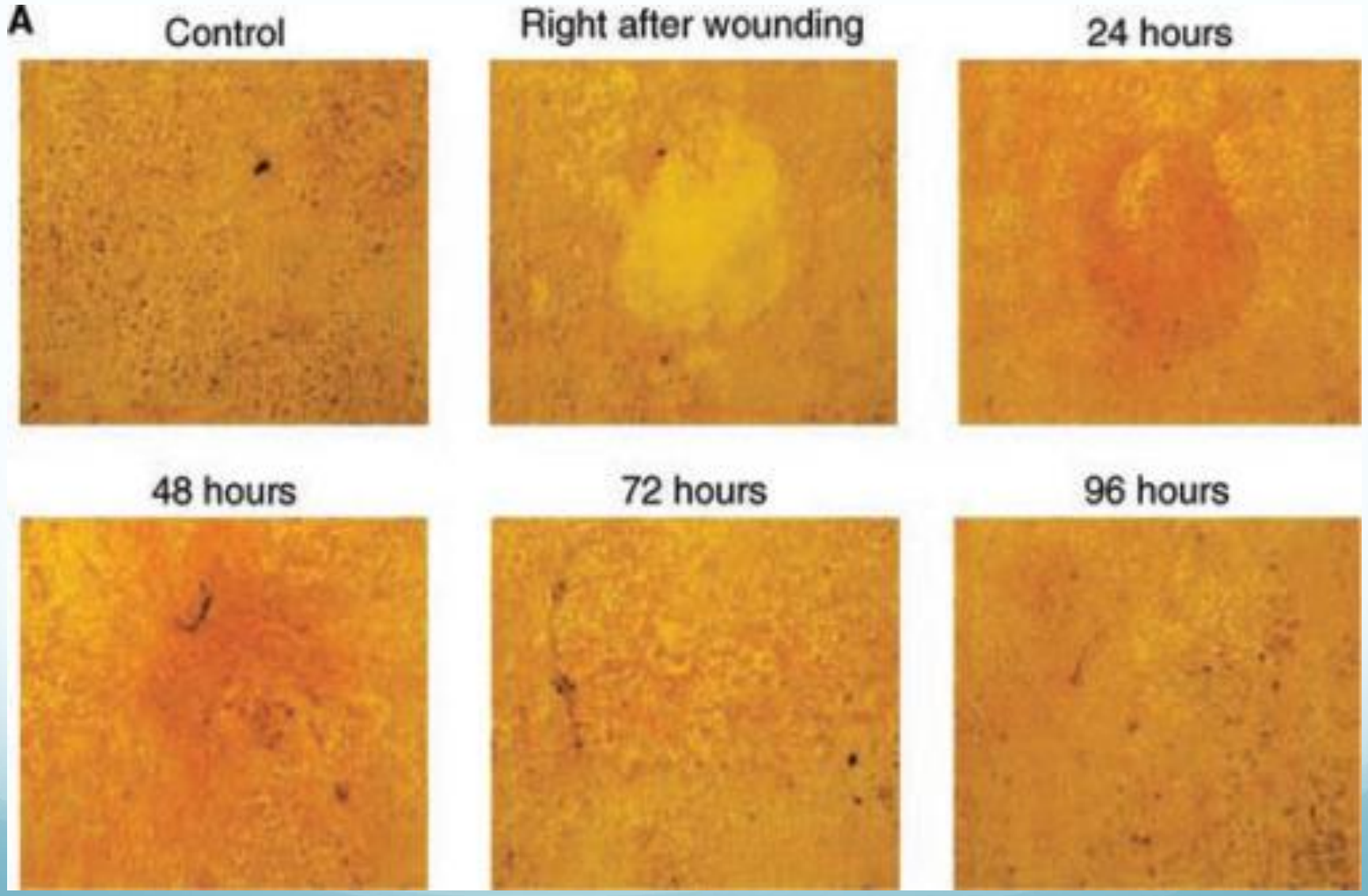

Future

- Simulators
- Tactile sensors on instruments,
- MR guided surgery,
- Endoscopic image + MR image (4th dimension)
- MR guided thermotherapy ablators,
- Glues and biologically active agents and specific site.

Tactile and Thermal sensors

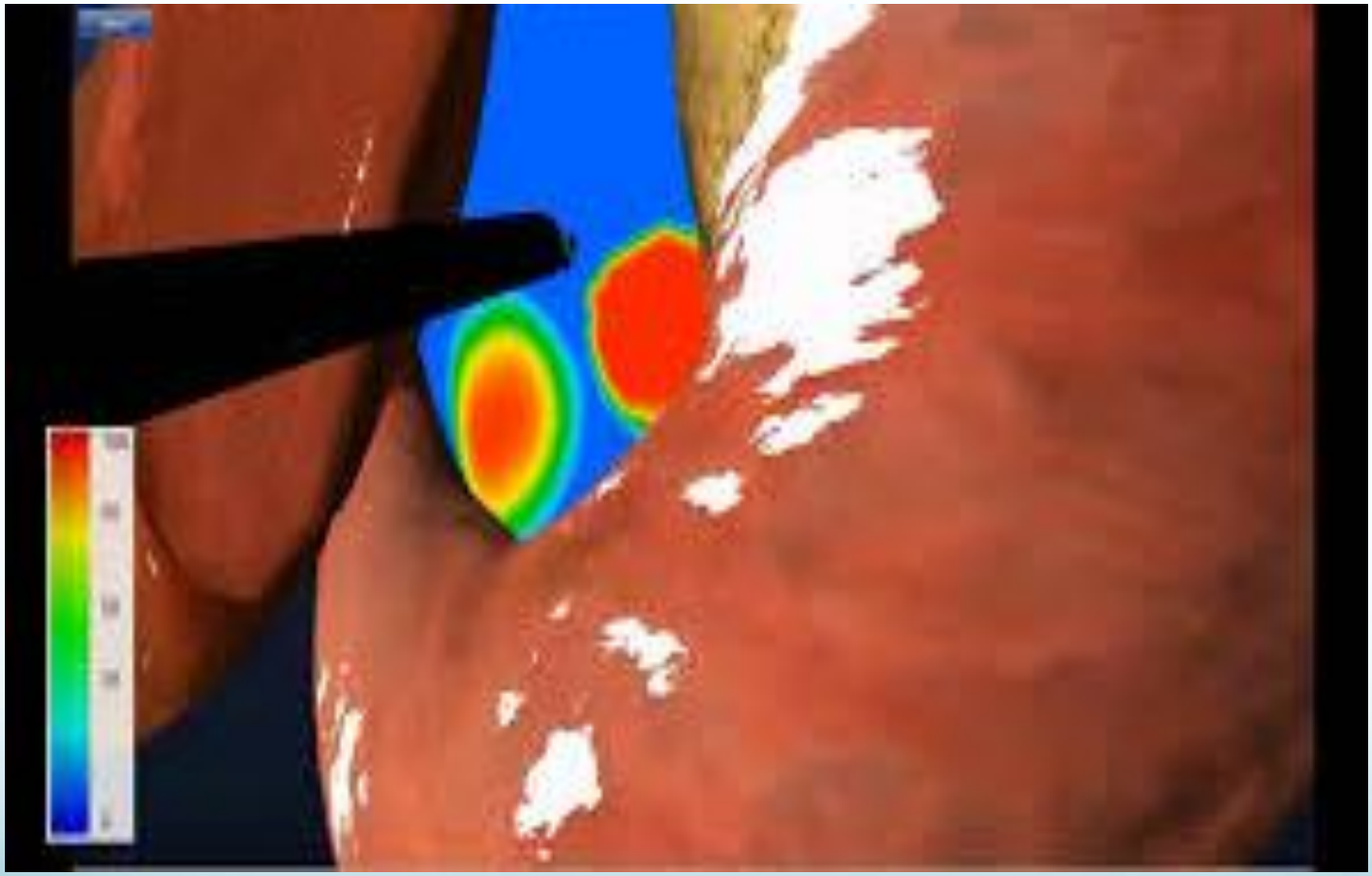

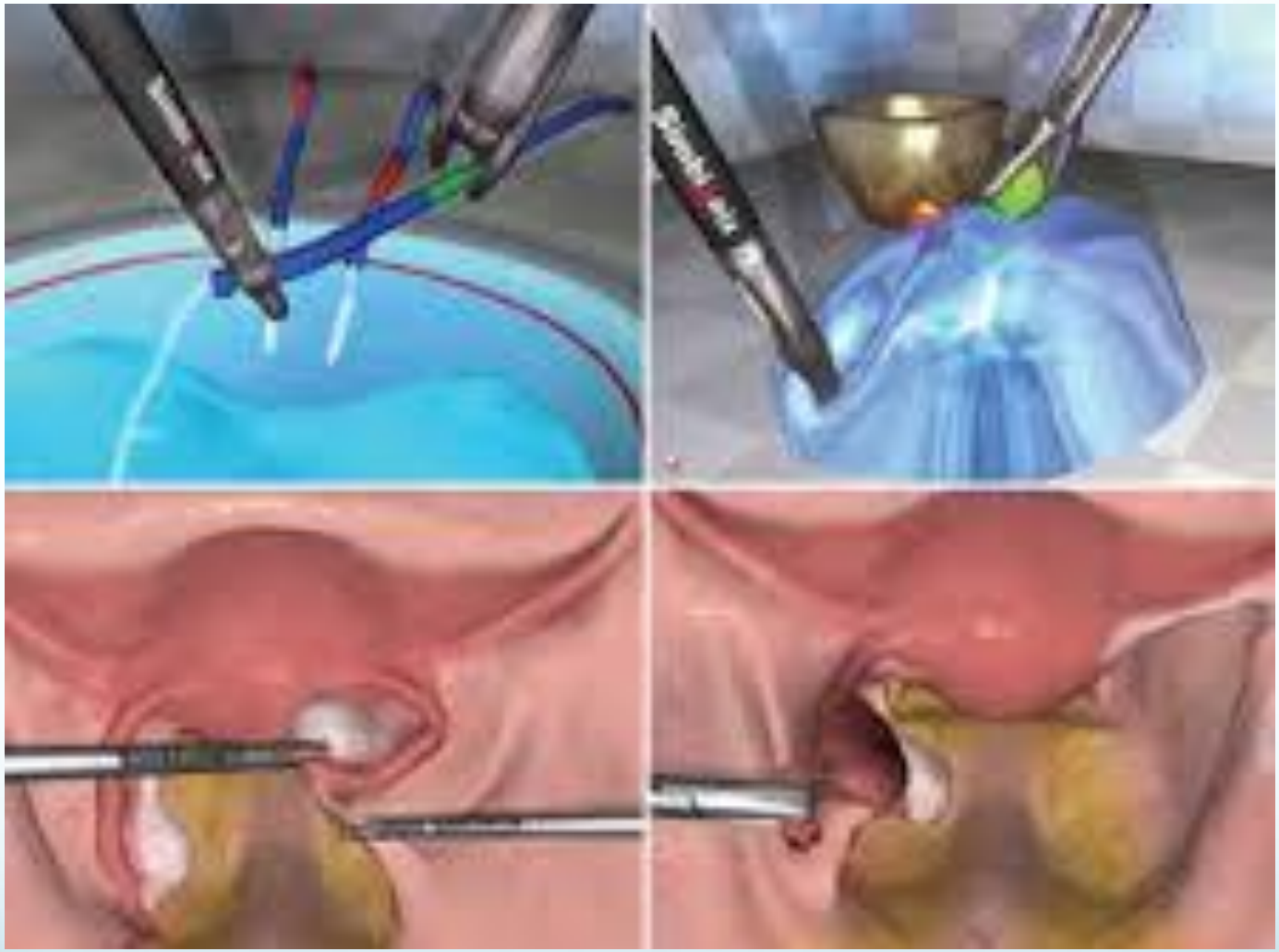

Combining MRI imaging

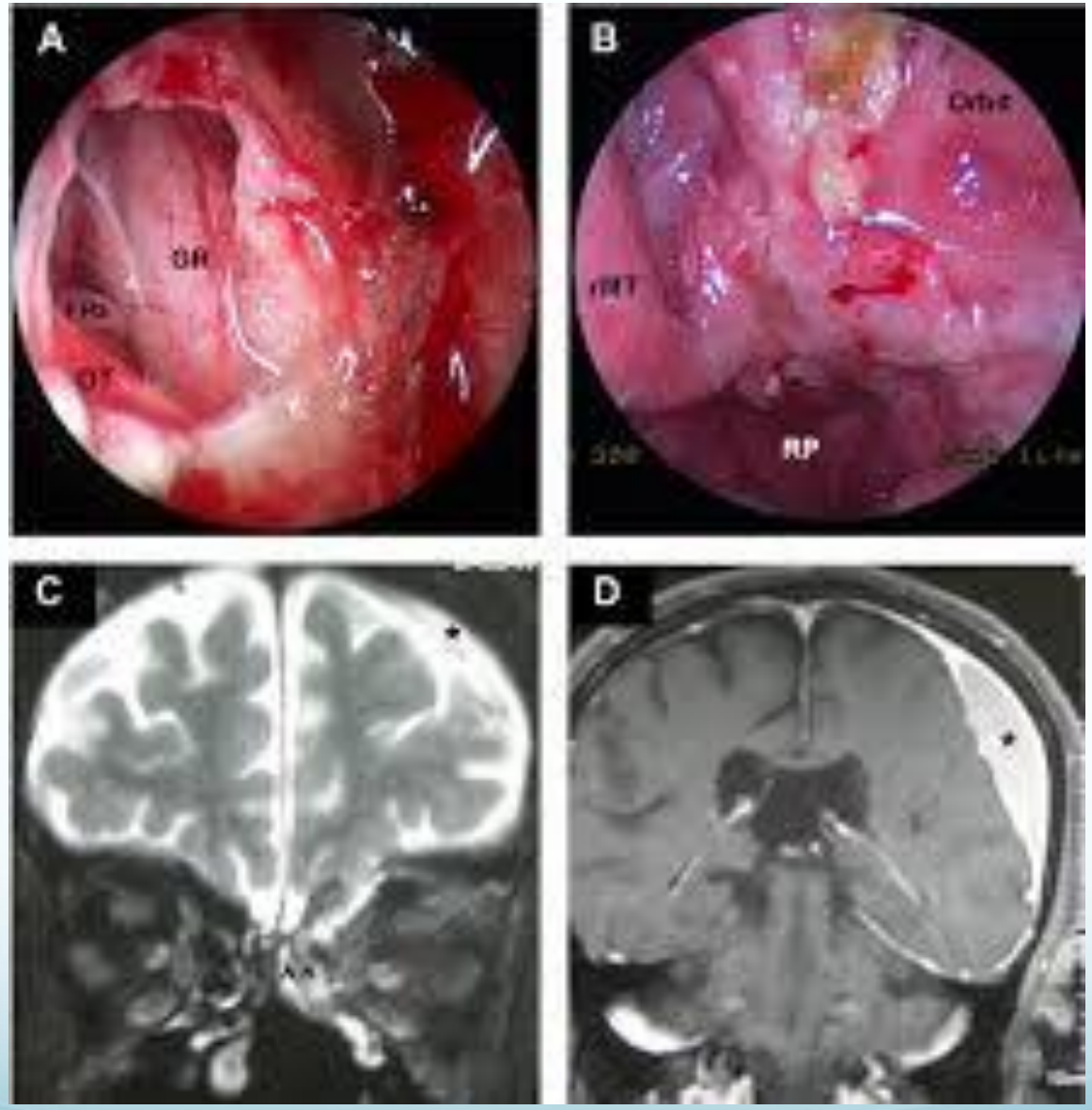
A
B
C
D
SR
OT
RP

- Every “ Useful innovation” goes through or should go through a ‘ shakedown’ process where it is evaluated objectively with rigor.

- I think laparoscopy has already been **shaken down.**

Vaginal surgery should not be replaced

- Laparolft
- LAM
- LAVH
- LA-SUI


HE LIKES TO DO EVERYTHING LIKE IN THE OPERATING THEATRE...
© www.OLAF-CARTOONS.DE
OLAF 2004-0062

- Laparoscopic circumcision
- Laparoscopic Episiotomy
- Laparoscopic vaginal delivery

- Obstet Gynecol. 2000 Jan;95(1):163-5.
- **Laparoscopic vaginal delivery: report of a case, literature review, and discussion.**
- Barham M[1].
- **Author information**
- **Abstract**
- I review the literature on laparoscopically assisted vaginal delivery, present and discuss a case, and describe the technique. Laparoscopically assisted vaginal delivery will emerge as a triumphant obstetric innovation that will radically transform operative obstetrics in the 21st century.
- **Comment in**
- Laparoscopic vaginal delivery: report of a case, literature review, and discussion. [Obstet Gynecol. 2000]

Is this what we want?
Surely NOT

Thank You